ISSN: 0974-6358 (P)
ISSN: 2583-3251 (O)

PEOPLE'S JOURNAL

PEOPLE'S JOURNAL OF SCIENTIFIC RESEARCH

AN INDEXED JOURNAL

VOLUME 18 ISSUE 2

July - Dec 2025

PEOPLE'S UNIVERSITY

Online access: www.pjsr.org

PEOPLE'S UNIVERSITY

PEOPLE'S JOURNAL OF SCIENTIFIC RESEARCH

GUIDELINES FOR MANUSCRIPT PREPARATION

1. **Title Page** should contain: type of manuscript, concise and informative title, running title, Name(s) of the author(s) with initials and surname, name of the department, institution & complete address with telephone number and e-mail of the corresponding author, total number of pages, total number of photographs and word counts for abstract and text (excluding references and abstract).

2. **Abstract:** The second page should carry the full title of the manuscript and an abstract (of no more that 150 words for case reports, brief reports and 250 words for original articles). The abstract should be structured and state the Background, Aims, Settings and Design, Materials & Methods, Statistical analysis used, Results and Conclusions. Below the abstract should provide 3 to 5 keywords.

3. **Introduction** – State the purpose of the article and summarize the rationale for the study or observation.

4. **Materials & Methods** should follow the introduction & should provide enough information to permit repetition of experimental work/ project, giving how the study was designed, carried out and data was analyzed. State whether study was approved by ethical committee or not. Describe statistical analysis methods used with required details. Give actual p-values, define statistical terms, symbols and abbreviations.

5. **Results** should describe the outcome of study giving relevant data. Avoid repeating in the text all the data depicted in tables or illustrations: **Tables** (numbered in arabic numerals) & **Illustrations** (Numbered in arabic numerals) should be prepared on separate sheet(s) with headings or legends. Minimum size of illustrations should be 8 x 10 cm. Bottom of figure should be marked by an arrow on it's back as well as figure's number and author's name on left side of photograph. Cite the tables/ figures in the text at appropriate places.

7. **Discussion** ordinarily should not be more than 1/3 of total length of manuscript. New and possible important findings of the study should be emphasized, as well as any conclusions that can be drawn. The Discussion should compare the present data to existing literature. The implications of the findings and their limitations, including potential for future research should be discussed. New hypotheses and clinical recommendations that are appropriate should be clearly identified.

8. **References** - In general, the number of references should not be exceed 40 for original articles, 50 for review articles and 15 for case reports. The authors are responsible for the accuracy and completeness of the references and their citations in the text. 1. References should be numbered consecutively in the order in which they are first mentioned in the text. 2. References in text, tables and legends should be identified by superscript numerals in square brackets [] at the end of the sentence outside any punctuation. If several different studies or papers are cited within one sentence, the number should be placed where it will accurately identify the correct study.

A. **Papers published in journals / periodicals: Authors surnames followed by initials of first names; full title of paper; full name of journal; year of publication, volume, issue (in Arabic Numerals), first & last page numbers eg.** Rocs DB. Congenital anomalies associated with thoracic outlet syndrome. Am J Surg 1976;132(3):771-778.

B. When writing a reference in text, the surname of the author should be given; if there are two authors, the surnames of both the authors should be given & if there are more than two authors, then surname of first author followed by "et al" and name(s) should be followed by year in bracket.

C1. **Books: Author's surnames and initials of first name; name of chapter (if any). In: full title of the book; Edition; Name & Domicile of Publisher; Year of Publication; pp (first & last page no.)** eg. Weiner JS. Human Biology, an introduction to human evolution, variation & growth. In: Human Ecology. W.A. Harrison, J.S. Weiner & N.A. Barnicat (Eds,), Ist Edn.; Oxford University Press, Philadelphia, 1964; pp 401-508.

9. All figures should be planned to fit within either 1 column width (8.0 cm), 1.5 column widths (13.0 cm) or 2 column widths (17.0 cm), and must be suitable for photocopy reproduction from the printed version of the manuscript.

   Although low quality images are adequate for review purposes, print publication requires high quality images to prevent the final product being blurred or fuzzy. Submit JPEG or TIFF files only. **MS PowerPoint and Word Graphics are unsuitable for printed pictures. Do not use pixel-oriented programmes. Scans (JPEG &TIFF only) should have a resolution of 300 dpi (halftone) or 600 to 1200 dpi (line drawings) in relation to the reproduction size.**

   All the Images/Figures should be submitted in separate files. Do not Zip the file.

10. **The corresponding author will receive a complimentary copy (only for print version of published article) .**

PEOPLE'S UNIVERSITY

PEOPLE'S JOURNAL OF SCIENTIFIC RESEARCH

Official Journal of People's University

ISSN: 0974-6358 (P)
ISSN: 2583-3251 (O)

CHIEF PATRON - Shri Suresh N. Vijaywargia, Hon'ble Chancellor, People's University, Bhopal, Madhya Pradesh, India

PATRON - Dr. Megha Vijaywargia, Pro-Chancellor, People's University, Bhopal, Madhya Pradesh, India

ADVISORY BOARD

CHIEF ADVISORS

Dr. Harish Rao, Vice Chancellor, People's University, Bhopal, Madhya Pradesh, India
Dr. Neerja Mallick, Registrar, People's University, Bhopal, Madhya Pradesh, India

ADVISORS

Dr. Rajesh Gaur, Dean, People's College of Medical Sciences & Research Centre,
People's University, Bhopal, Madhya Pradesh, India

ASSOCIATE EDITORS

Dr. Sanjeev Tyagi, Dean, People's Dental Academy,
People's University, Bhopal, Madhya Pradesh, India

Dr. Parimala Kulkarni, Dean, People's College of Dental Sciences,
People's University, Bhopal, Madhya Pradesh, India

Dr. Bhaskar Kumar Gupta, Principal, School of Pharmacy & Research,
People's University, Bhopal, Madhya Pradesh, India

Prof. Dr. Punithalakshmi K, Principal, People's College of Nursing & Research Centre,
People's University, Bhopal, Madhya Pradesh, India

EDITOR - IN - CHIEF

Dr. Anish Gupta
Professor & Head,
Department of Oral Pathology & Microbiology, People's Dental Academy, People's University, Bhopal, Madhya Pradesh, India

Technical Staff

Mr. Mohd Javed, Journal Coordinator, People's University, Bhopal, Madhya Pradesh, India

EDITORIAL ADVISORS

National

Dr. Ashok Johari
Director, Paediatric Orthopaedics,
B. Nanavati Super Speciality Hospital,
Mumbai, Maharashtra, India

Dr. Himanshu Kumar,
Professor,
Immunology, Indian Institute of Science Education
and Research, Bhopal, Madhya Pradesh, India

Dr. Ganesh Ranganath Jadhav
Assistant Professor,
Department of Dentistry,
All Institute of Medical Sciences & Research Centre
(AIIMS), Nagpur, Maharashtra, India

International

Dr. Sandeep Poddar
Deputy Vice Chancellor (Research & Innovation)
Lincoln University, Malaysia

Dr. Amith H.V.
Assistant Professor
Department of Preventive Dentistry, Faculty of Dentistry,
Taif University, Kingdom of Saudi Arabia

PEOPLE'S UNIVERSITY

PEOPLE'S JOURNAL OF SCIENTIFIC RESEARCH

INDEXED JOURNAL:

Index Copernicus
Google Scholar
EBSCO host
Indian Citation Index
IP Indexing
National Science Library (NISCAIR)

Index Copernicus value (ICV 2024)	:	99.97
International Impact Factor Services (IIFS)	:	4.35
IP Indexing IPI value	:	2.58

Full Text of articles available in PDF format
on
(www.pjsr.org; http://peoplesuniversity.edu.in)

Annual Subscription of Journal	:	Individual	2000/-
		Library	2500/-
		(Trade discount of 10 % for agencies only)	

Copyright © 2025, People's University. All right reserved.
No part of the publication may be transmitted in any form or by any means, electronic or mehcanical, without permission from the Editor-In-Chief.

For subscription, send A/C payee demand draft in favour of **"People's University"** payable at Bhopal and may be sent to **Dr. Anish Gupta, Editor - In - Chief**, People's Journal of Scientific Research, Room 33, 3rd Floor, People's University Building, Bhanpur, Bhopal-462037

Research Article

Undergraduate Dental Students' Perceptions of Periodontics Training: A Cross-Sectional Questionnaire Survey

Madhumitha C, Rajesh Gaikwad, Akshaya Banodkar, Nilofar Attar, Nandini Metaliya, Akhrienuo Kiso

Department of Periodontology, Government Dental College and Hosital, Mumbai (Maharashtra)

ABSTRACT:

Background: Periodontal diseases are highly prevalent and require every dental graduate to be competent in their prevention and management. Understanding students' perceptions of undergraduate periodontics training is essential to align curricula with competency-based education.

Aim: To evaluate undergraduate dental students' perceptions of the adequacy of periodontics training in the Bachelor of Dental Surgery (BDS) programme.

Materials & Methods: A cross-sectional, questionnaire-based survey was conducted among 300 BDS students (third year, final year and interns). A structured, content-validated questionnaire assessed perceptions of theoretical teaching, clinical exposure, confidence in managing periodontal conditions and teaching methods. Data were analysed using descriptive statistics and Chi-square tests to explore associations between academic year and key perception variables.

Results: Approximately half of the respondents perceived the theoretical content in periodontics as sufficient and felt that the curriculum emphasized its importance in oral health. Fewer than half reported sufficient hands-on experience with non-surgical periodontal therapy, and only about one-third had assisted or observed periodontal surgeries. Confidence in diagnosing and managing basic periodontal conditions was moderate, with many students reporting a need to improve their knowledge and clinical skills. Most respondents expressed a desire for more workshops, additional clinical hours, and use of technology-enhanced teaching. Intention to specialize in periodontics, perceived need for technology, and viewing periodontics as essential for general practice showed significant associations with academic year ($p<0.05$).

Conclusion: Despite positive views of undergraduate periodontics teaching, notable gaps in clinical exposure and self-reported confidence persist, highlighting the need to strengthen competency-based, hands-on, and technology-supported training in periodontology.

KEY WORDS: Periodontics education, Dental students, Curriculum, Clinical competence

Address for correspondence : Dr. Madhumitha C, 215 Department of Periodontology, Government Dental College and Hospital, Mumbai- 400001 (Maharashtra) , India, E-mail: cm.maddy99@gmail.com

Submitted: 07.08.2025, **Accepted:** 10.12.2025, **Published:** 18.12.2025

INTRODUCTION:

Periodontal diseases represent one of the most prevalent chronic inflammatory conditions worldwide and are a leading cause of tooth loss in adults[1,2]. They contribute substantially to disability-adjusted life years and economic burden, and recent global estimates indicate that the prevalence and impact of periodontitis are either stable at high levels or increasing in many regions[1–3]. Beyond their local effects on the supporting tissues of the teeth, periodontal diseases have well-documented associations with major systemic

Access this article online

Quick Response Code:	Website: www.pjsr.org
	DOI: https://doi.org/10.5281/zenodo.17974550

This is an open access journal, and articles are distributed under the terms of the Creative Commons Attribution-Non Commercial ShareALike 4.0 License, which allows others to remix, tweak, and build upon the work non-commercially, as long as appropriate credit is given and the new creations are licensed under the identical terms.

For reprints contact: editor.pjsr@peoplesuniversity.edu.in

How to cite this article: Madhumitha C, Gaikwad R, Bandokar A, Attar N, Metaliya N, Kiso A. Undergraduate Dental Students' Perceptions of Periodontics Training: A Cross-Sectional Questionnaire Survey. PJSR. 2025;18(2):01-10.

conditions such as diabetes mellitus, cardiovascular disease and adverse pregnancy outcomes, underscoring their relevance to general health and wellbeing[2,4,5]. In this context, periodontics is a core component of the Bachelor of Dental Surgery (BDS) curriculum and forms a critical foundation for comprehensive oral healthcare and long-term treatment success.

Undergraduate periodontics training typically includes didactic teaching, preclinical exercises and clinical exposure to non-surgical and, to a more limited extent, surgical periodontal therapy. Ideally, this integrated training should equip students with sound theoretical knowledge, clinical decision-making skills, and confidence in performing essential periodontal procedures such as scaling and root planing, basic flap surgery, and maintenance therapy. However, in many institutions, students' clinical experience in periodontics is influenced by factors such as patient availability, competition for cases across departments, faculty-student ratios, and the organization and timing of clinical postings[6]. These structural constraints can create discrepancies between the competencies expected of new graduates and their actual preparedness for independent practice.

Globally, there has been a marked shift towards competency-based dental education, with increasing emphasis on clearly defined outcomes, workplace-based assessment, and the integration of knowledge, skills, and professional behaviours[6–8]. Within this framework, it becomes essential to periodically evaluate whether existing periodontics teaching and clinical training genuinely meet the needs of graduating dentists, rather than relying solely on curriculum documents and regulatory prescriptions. Student perceptions offer a particularly valuable lens through which gaps in curriculum design, teaching methods, clinical exposure, and assessment strategies can be identified. Recent surveys in different settings suggest that, despite reasonable levels of theoretical awareness, dental undergraduates often report limited confidence in periodontal diagnosis, treatment planning, and management, and express a need for more structured and intensive clinical training in periodontics[9,10]. However, systematic evidence from the Indian BDS context remains sparse, especially with respect to how students themselves perceive the adequacy and effectiveness of their undergraduate periodontics training. Understanding these perceptions is essential for informing evidence-based curricular refinement and ensuring that future graduates are confident and competent in delivering periodontal care as an integral part of general dental practice.

MATERIALS & METHODS:-

Study design and setting:

This was a cross-sectional, questionnaire-based survey conducted among undergraduate Bachelor of Dental Surgery (BDS) students to assess their perceptions regarding the adequacy of Periodontics training in the undergraduate curriculum. The study was carried out in the Department of Periodontics of a dental teaching institution. Participation was voluntary and anonymous; no personal identifiers were collected apart from non-mandatory institutional details. Electronic or written informed consent was obtained from all participants before they completed the questionnaire. Confidentiality of the data was maintained throughout, and the information was used solely for research and academic purposes.

Participants and sampling:

The study population comprised undergraduate BDS students who had formal exposure to Periodontics as part of their curriculum. Students enrolled in the third year, fourth year, and internship of the BDS curriculum were invited to participate, as they would have completed or be undergoing clinical postings in Periodontics. First- and second-year students were excluded because they had minimal or no clinical exposure in Periodontics at the time of data collection. A total of 300 students who met the eligibility criteria and provided consent completed the questionnaire and were included in the final analysis. A convenience sampling approach was adopted, wherein all eligible students present during the data collection period were approached and invited to participate.

Inclusion and exclusion criteria:

Inclusion criteria were: (i) BDS students enrolled in third year, final year, or internship; and (ii) willingness to participate and provide informed consent. Exclusion criteria were: (i) first- and second-year BDS students; (ii) students who declined participation; and (iii) incomplete or blank questionnaires.

Questionnaire development:

Data were collected using a structured, self-administered questionnaire in English, specifically designed for this study based on a review of the literature and the learning objectives of the undergraduate Periodontics curriculum. The questionnaire comprised six sections:

1. general information (academic year, clinical rotations in Periodontics, intention to specialize);

2. curriculum and training content (sufficiency of theoretical content, emphasis on Periodontics within overall oral health care, additional topics required);
3. clinical experience (hands-on exposure to non-surgical therapy, observation/assistance in surgeries, confidence in diagnosis and management, referral decisions, exposure to complex cases and interdisciplinary management);
4. teaching methods and resources (usefulness of demonstrations, technology-enhanced learning, awareness of modern techniques, confidence with advanced instruments);
5. overall satisfaction; and
6. overall evaluation of Periodontics training.

Most items were close-ended, including dichotomous (yes/no), multiple-choice, and Likert-scale response formats. A few questions allowed multiple responses (e.g., topics needing more attention, perceived challenges, and preferred additional resources). Face and content validity of the questionnaire were established by senior faculty members in Periodontics and dental education, and minor modifications in wording and sequence were made based on their feedback to improve clarity and relevance.

Data collection procedure:

The questionnaire was administered as a self-completed survey either in electronic format (Google Forms) circulated through institutional academic channels (e-mail/WhatsApp groups) or as printed copies distributed during scheduled teaching sessions, depending on logistical feasibility. The first page of the form contained a brief description of the study and an informed consent statement. Students who agreed to participate proceeded to complete the questionnaire. Participation was voluntary, and no incentives were offered. To minimize response bias, students were instructed to complete the questionnaire individually without discussion with peers. Completed responses were compiled into a single database for analysis.

Data management and statistical analysis:

All responses were exported into a Microsoft Excel spreadsheet, checked for completeness and consistency, and then imported into Statistical Package for the Social Sciences (SPSS) software (version 26.0; IBM Corp., Armonk, NY, USA) for analysis. Categorical variables were summarized using frequencies and percentages. For questions with Likert-scale responses, distributions across response categories were similarly expressed as percentages. For items where comparisons across academic year (third year, final year, and internship) were relevant, associations between academic year and response categories were assessed using the Chi-square test. Where expected cell counts were small, Fisher's exact test was applied. A p-value of <0.05 was considered statistically significant.

RESULTS:

Participant characteristics and general information:

A total of 300 undergraduate BDS students participated in the survey. As per the inclusion criteria, all respondents were from the clinical years of training, with no first- or second-year students included. The sample comprised third-year (29.7%), final-year (35.3%), and internship (35.0%) students, with final-year students forming the largest subgroup (Table 1).

Less than half of the respondents (42.3%) reported that they had completed clinical rotations in Periodontics, indicating that a substantial proportion were either still undergoing or yet to begin formal clinical postings in this specialty. Only a small fraction (12.7%) expressed an intention to pursue specialization in Periodontics. While completion of clinical rotations did not show a statistically significant association with academic year (p=0.512), the intention to specialize in Periodontics varied significantly across years of study (p=0.002), suggesting that exposure and progression through the course may influence students' career preferences (Table 1).

Perceptions of theoretical training and teaching approaches:

Just over half of the respondents felt that the theoretical component of Periodontics in their curriculum was adequate, with 50.3% indicating that the theoretical content was sufficient. However, only 40.0% agreed that the curriculum clearly emphasized the importance of Periodontics in overall oral health care, suggesting a possible gap between content volume and its perceived positioning within the broader framework of dental education. These perceptions did not differ significantly across academic years (p=0.981 and p=0.781, respectively), indicating a relatively consistent experience of theory across the clinical years.

With regard to the quality and delivery of teaching, most students reported that lectures on periodontal diseases had prepared them reasonably well for clinical practice, with the largest proportion rating them as "adequate" or "very well" preparatory. Similarly, the balance between theoretical and clinical

Table 1: Participant characteristics and general information (N = 300)

Variable	Category	n	%	*p-value**
Academic year	Third year	89	29.7	-
	Final year	106	35.3	
	Internship	105	35.0	
Completed clinical rotations in Periodontics	Yes	127	42.3	0.512
Plan to pursue specialization in Periodontics	Yes	38	12.7	0.002†

* *p*-value for association with academic year (Chi-square test) ; † Statistically significant ($p < 0.05$)

Table 2: Perceptions of theoretical training and teaching approaches in Periodontics (N = 300).

Domain	Item	Response category	n	%	*p-value**
Theoretical adequacy	Theoretical content in Periodontics is sufficient	Yes	151	50.3	0.981
		No/Maybe	149	49.7	
Curriculum emphasis	Curriculum emphasizes importance of Periodontics in overall oral health care	Yes	120	40.0	0.781
		No/Not sure	180	60.0	
Practical demonstrations	Practical demonstrations/simulations are helpful	Yes	150	50.0	1.000
		No/Somewhat	150	50.0	
Technology in teaching	There should be more use of technology to teach periodontal procedures	Yes	260	86.7	0.003 †
		No	40	13.3	
Awareness of modern techniques	Aware of modern techniques such as laser-assisted periodontal therapy	Yes	174	58.0	0.813
		No	126	42.0	
Lecture effectiveness	Lectures on periodontal diseases have prepared you for clinical practice	Very well	77	25.7	N/A
		Adequately	121	40.3	
		Not sure	90	30.0	
		Not adequate	12	4.0	
Theory–clinical balance	Balance between theoretical and clinical training in Periodontics	Excellent	59	19.7	
		Very good	55	18.3	
		Good	129	43.0	
		Fair	47	15.7	
		Poor	10	3.3	

* *p*-value for association with academic year (Chi-square test) where applicable ; † Statistically significant ($p < 0.05$)

training in Periodontics was predominantly rated as "good" to "excellent," although a non-negligible minority considered this balance only "fair" or "poor," pointing to scope for further integration of theory with clinical exposure. Half of the respondents perceived practical demonstrations or simulations as helpful in their training, and a large majority (86.7%) expressed a clear desire for greater use of technology,

Table 3: Perceived gaps in Periodontics curriculum and additional topics desired (N = 300*).

Domain	Item	n	% of students
Topics requiring more attention in current curriculum	Diagnosis of periodontal diseases	128	42.7
	Non-surgical periodontal therapy	80	26.7
	Periodontal surgery techniques	123	41.0
	Management of advanced periodontitis	110	36.7
	Periodontal maintenance and patient follow-up	69	23.0
	Link between periodontal disease and systemic health	121	40.3
	Instrumentation and basics of Periodontics	59	19.7
Additional theoretical topics desired	Periodontal–systemic health connections	53	17.7
	Basics of periodontal regeneration	30	10.0
	Gingival aesthetics and smile design	39	13.0
	Introduction to laser and digital Periodontics	38	12.7
	Periodontal risk assessment	37	12.3
	Minimally invasive periodontal therapies	35	11.7

* Multiple responses allowed; percentages do not sum to 100%.

such as videos and simulation software, in teaching periodontal procedures. This preference for technology-enhanced learning showed a statistically significant association with academic year (p=0.003), reflecting evolving expectations and learning styles as students progress through the course. Awareness of modern techniques such as laser-assisted periodontal therapy was reported by 58.0% of students, with no significant variation across years of study (p=0.813), indicating moderate but not universal familiarity with contemporary periodontal modalities (Table 2).

Perceived gaps in curriculum content:

Students identified several domains within Periodontics that they felt required greater emphasis in the undergraduate curriculum. The most frequently cited areas were diagnosis of periodontal diseases and periodontal surgery techniques, followed closely by the link between periodontal disease and systemic health and management of advanced periodontitis. Topics such as periodontal maintenance and patient follow-up and instrumentation and basics of Periodontics were also selected, though by comparatively fewer students, indicating that while core diagnostic and surgical aspects are seen as priority areas, supportive and basic skill domains are not perceived as fully addressed either.

When asked about additional theoretical content they would like incorporated, students expressed clear interest in more contemporary and advanced topics. Notably, periodontal-systemic health connections and gingival aesthetics and smile design were frequently requested, alongside introduction to laser and digital Periodontics, periodontal risk assessment, and minimally invasive periodontal therapies. The desire for content covering periodontal regeneration further reflects students' expectations that the curriculum should better align with current scientific advances and evolving clinical practice in Periodontics (Table 3).

Clinical exposure and self-reported confidence:

Students' clinical exposure to Periodontics was variable and, in many respects, limited. Fewer than half of the respondents (44.0%) felt that they had received sufficient hands-on experience with non-surgical periodontal therapy such as scaling and root planing. Only one-third (33.3%) reported having had the opportunity to assist or observe periodontal surgeries, and just 38.7% had participated in interdisciplinary discussions or case studies involving Periodontics and other specialties. None of these exposure variables showed a statistically significant association with academic year (all $p > 0.05$), indicating that the perceived limitations in clinical experience were relatively consistent across the clinical phases of training. In terms of patient load, only about one-quarter of students (26.3%) reported that they frequently treated patients with periodontal diseases during clinical postings, while the majority described such encounters as only occasional, rare, or absent, suggesting that authentic clinical exposure to periodontal cases may be insufficient for many undergraduates (Table 4).

Table 4: Clinical exposure and self-reported confidence in Periodontics (N = 300*).

Domain	Item	Response category	n	%	*p*-value†
Clinical exposure	Sufficient hands-on experience with non-surgical periodontal therapy	Yes	132	44.0	0.683
		No	168	56.0	
	Opportunity to assist/observe periodontal surgeries	Yes	100	33.3	0.265
		No	200	66.7	
	Participation in interdisciplinary discussions/case studies	Yes	116	38.7	0.588
		No	184	61.3	
	Frequency of treating patients with periodontal diseases during postings	Frequently	79	26.3	–
		Occasionally	128	42.7	
		Rarely	48	16.0	
		Never	45	15.0	
Confidence – basic management	Confidence in diagnosing and managing basic periodontal conditions	Highly confident	40	13.3	–
		Moderately confident	102	34.0	
		Needs improvement in knowledge	111	37.0	
		Needs improvement in skills	47	15.7	
Confidence – referral decision	Confidence in determining which patients can be managed vs referred to specialist	Yes, I am confident	67	22.3	–
		I am somewhat confident	106	35.3	
		I am unsure	53	17.7	
		No, I am not confident	74	24.7	
Complex case management	Preparedness to handle complex interdisciplinary periodontal cases	Confident	86	28.7	–
		Under-confident	150	50.0	
		No confidence	64	21.3	
Advanced instruments	Confidence using advanced instruments/techniques (e.g., ultrasonic scalers)	Very confident	106	35.3	–
		Under-confident	119	39.7	
		Not confident	75	25.0	

Challenges encountered and perceived resource needs:

Students reported several barriers that impeded their learning and clinical skill acquisition in Periodontics. The most frequently cited challenge was a lack of hands-on practice, indicating that many students felt they did not have adequate opportunity to perform periodontal procedures themselves, even

Table 5: Reported challenges and suggested resources for improving Periodontics training (N = 300*)

Domain	Item	n	% of students
Challenges faced	Lack of clinical exposure	85	28.3
	Limited access to diverse cases	143	47.7
	Inadequate faculty support	51	17.0
	Lack of hands-on practice	177	59.0
	Other	0	0.0
Resources suggested	Workshops	198	66.0
	Additional clinical hours	153	51.0
	Seminars	64	21.3

* Multiple responses allowed; percentages do not sum to 100%.

when they were exposed to clinical postings. This was closely followed by limited access to diverse cases, reflecting concerns that the range and complexity of periodontal presentations encountered during training were insufficient to build comprehensive clinical competence. A notable proportion of respondents also reported lack of clinical exposure more generally, suggesting that both the quantity and quality of clinical encounters may be suboptimal. Fewer students identified inadequate faculty support as a challenge, but this still represents an important organizational factor that can influence supervision, feedback, and confidence-building in clinical settings. No respondents indicated any additional challenges beyond the predefined categories, implying that these four domains captured the main perceived obstacles in clinical Periodontics training.

In parallel, students indicated clear preferences for strategies and resources that could help strengthen their training. Workshops were the most commonly suggested intervention, reflecting a desire for focused, skill-based sessions that allow intensive practice and interaction. More than half of the students felt that additional clinical hours would enhance their learning, aligning with their perception of limited hands-on experience and case diversity. A smaller, though still relevant, proportion of respondents expressed interest in seminars, which may support deeper theoretical understanding, case-based discussions, and updates on emerging concepts. Collectively, these responses underscore that students are not only aware of existing gaps but also proactive in identifying practical, experience-oriented solutions to improve Periodontics training (Table 5).

Overall satisfaction and global evaluation of Periodontics training:

Global perceptions of Periodontics training were generally positive, although a substantial students expressed only moderate enthusiasm or uncertainty. In terms of overall satisfaction, just over half of the respondents reported being either very satisfied or satisfied with their Periodontics training, while almost two-fifths described themselves as neutral. Only a small minority were dissatisfied or very dissatisfied. Similarly, when asked to rate the current Periodontics training in their dental program, the majority of students graded it as good, very good or excellent, with relatively few assigning a fair or poor rating. These findings suggest that, despite perceived gaps in specific domains such as hands-on experience and exposure to complex cases, students still view their Periodontics teaching in broadly favorable terms at an overall program level.

However, when the focus shifted from satisfaction to perceived preparedness, a more cautious pattern emerged. Fewer than half of the students felt prepared to manage periodontal cases at the start of independent clinical practice, and approximately two-thirds believed that their training had equipped them to address real-world challenges. Notably, a very high proportion of students considered Periodontics to be an essential foundation for general dental practice, and this perception showed a statistically significant association with academic year ($p = 0.006$), indicating that appreciation of the discipline's importance increases as students advance through the course. Taken together, these results highlight a nuanced picture: students generally rate their training and are satisfied with it, yet many remain unsure about their readiness to manage periodontal care independently, underscoring the need to translate positive perceptions into stronger competence and confidence (Table 6).

DISCUSSION:

The present study explored undergraduate dental students' perceptions of the adequacy of periodontics training across theory, clinical exposure, confidence, and overall satisfaction. Overall, about half

Table 6: Overall satisfaction, global rating, and perceived preparedness in Periodontics (N = 300).

Domain	Item	Response category	n	%	*p-value**
Perceived preparedness	Feel prepared to manage periodontal cases at start of practice	Yes	141	47.0	0.784
		No/Unsure	159	53.0	
	Training has prepared you to address real-world challenges	Yes	186	62.0	0.214
		No	114	38.0	
Perception of importance	Consider Periodontics an essential foundation for general dental practice	Yes	256	85.3	0.006 †
		No	44	14.7	
Overall satisfaction	Overall satisfaction with Periodontics training	Very satisfied	62	20.7	–
		Satisfied	100	33.3	
		Neutral	118	39.3	
		Dissatisfied	16	5.3	
		Very dissatisfied	4	1.3	
Global rating of training	Overall rating of current Periodontics training	Excellent	66	22.0	–
		Very good	64	21.3	
		Good	123	41.0	
		Fair	40	13.3	
		Poor	7	2.3	

* *p*-value for association with academic year (Chi-square test) where applicable ;; † Statistically significant ($p < 0.05$)

of the respondents felt that the theoretical content in periodontics was sufficient and that the curriculum broadly emphasized its importance in oral health care, and a large majority regarded periodontics as an essential foundation for general dental practice. At the same time, many students expressed only moderate confidence in diagnosing and managing periodontal conditions, reported limited hands-on experience, particularly with surgical procedures, and frequently highlighted a lack of opportunities to treat diverse periodontal cases. This pattern suggests a disconnect between awareness of the discipline's importance and students' perceived readiness to independently manage periodontal care.

These findings are consistent with emerging literature on undergraduate perceptions of periodontology. Lande et al., in a recent review, reported that while undergraduates generally recognize the central role of periodontics in maintaining oral function and supporting other restorative and implant procedures, they often view it as a vast and conceptually demanding subject and do not consistently see it as an attractive career option[11]. A preliminary survey from Tamil Nadu similarly showed that a majority of interns found periodontal terminology difficult, had not observed key procedures such as periodontal surgeries or laser therapy, and were uncertain about choosing periodontology as a postgraduate specialty[12]. The relatively low proportion of students in our study who expressed interest in specializing in periodontics mirrors these reports and underscores the need to improve how the subject is taught and positioned within the curriculum[11,12].

The tension between "adequate teaching" and "insufficient confidence" is also reflected in international work on periodontal education. Mofidi et al. found that Canadian dental students demonstrated acceptable knowledge in periodontal diagnosis and treatment planning when benchmarked against expert answers, yet still reported a lack of confidence and identified specific pedagogical issues in both preclinical and clinical teaching[13]. Our respondents likewise reported that lectures were generally adequate, but a substantial proportion felt they needed improvement in knowledge and especially in hands-on

skills. The relatively modest exposure to non-surgical and surgical periodontal procedures, and the high proportion of students who felt under-confident in managing complex or interdisciplinary cases, suggest that case volume, case mix, and structured supervision during clinical postings may be limiting factors. This contrasts with the very high satisfaction levels reported in a recent Saudi study where students described well-organized clinical periodontics courses with ample opportunities to practise skills, clear learning objectives, and a supportive learning environment, highlighting how program design and resources can markedly influence student perceptions[14].

Students in the present study strongly endorsed the need for more workshops, additional clinical hours, and better use of technology such as videos, simulations, and digital tools. This aligns with European consensus recommendations on undergraduate periodontal education, which call for integrating modern learning approaches, small-group activities, simulation, and structured clinical assessment, alongside traditional lectures to build procedural competence and professional behaviours[15]. The high demand for additional content on periodontal–systemic links, regeneration, minimally invasive techniques, and digital/laser periodontics suggests that curricula may lag behind contemporary practice, a gap also noted in multi-country surveys on periodontal education and in reviews advocating more exposure to advanced procedures earlier in training[11,16,17]. Recent commentaries on competency-based periodontal education further emphasise mapping clear competencies, aligning assessments with those competencies, and incorporating reflective feedback and OSCE-style evaluations, directions that dovetail with the enhancement areas identified by our respondents[17].

This study has some limitations that should be considered when interpreting the findings. Its cross-sectional design captures perceptions at a single time point and cannot establish how confidence or satisfaction evolve as students progress through training. The sample was drawn from a limited number of institutions and relied on voluntary participation, which may introduce selection and response bias and limit generalizability to all Indian dental colleges with differing infrastructure, patient flow, and teaching philosophies. Self-reported measures of confidence and preparedness may not directly reflect objective competence, and although the questionnaire covered key domains of theory and clinical training, more detailed psychometric validation and triangulation with performance data (e.g., OSCE scores, logbooks) would strengthen inferences. Future work should therefore include multi-centre, longitudinal studies that correlate students' perceptions with objective outcomes, explore faculty perspectives, and evaluate the impact of targeted interventions, such as simulation-based modules, structured surgical observation, and competency-based assessments, on students' readiness to deliver independent periodontal care.

CONCLUSION:

Findings of the present study indicate that while undergraduate dental students generally value periodontics and rate their training favourably, many do not feel sufficiently confident or clinically exposed to manage periodontal conditions independently, especially complex or interdisciplinary cases. Perceived gaps centred around limited hands-on experience, restricted case diversity, and insufficient coverage of advanced and contemporary topics such as regeneration, minimally invasive approaches, and digital/laser-assisted periodontics. At the same time, students clearly articulated practical solutions, including more workshops, extended clinical hours, and greater use of technology-enhanced teaching. Strengthening competency-based periodontal education by addressing these areas may help bridge the gap between theoretical understanding and clinical preparedness, ultimately producing graduates better equipped to deliver comprehensive periodontal care in general dental practice.

Financial Support and Sponsorship

Nil.

Conflicts of Interest

There are no conflicts of interest.

REFERENCES:

1. Jin LJ, Lamster IB, Greenspan JS, Pitts NB, Scully C, Warnakulasuriya S. Global burden of oral diseases: emerging concepts, management and interplay with systemic health. Oral Dis. 2016 Oct;22(7):609-19. doi: 10.1111/odi.12428. Epub 2016 Jan 20. PMID: 26704694.
2. Nazir MA. Prevalence of periodontal disease, its association with systemic diseases and prevention. Int J Health Sci (Qassim). 2017 Apr-Jun;11(2):72-80. PMID: 28539867; PMCID: PMC5426403.
3. Hashim NT, Babiker R, Padmanabhan V, Ahmed AT, Chaitanya NCSK, Mohammed R, Priya SP, Ahmed A, El Bahra S, Islam MS, Gismalla BG, Rahman MM. The Global Burden of Periodontal Disease: A Narrative Review on Unveiling Socioeconomic and Health

Challenges. Int J Environ Res Public Health. 2025 Apr 16;22(4):624. doi: 10.3390/ijerph22040624. PMID: 40283848; PMCID: PMC12027323.

4. Casanova L, Hughes FJ, Preshaw PM. Diabetes and periodontal disease: a two-way relationship. Br Dent J. 2014 Oct;217(8):433-7. doi: 10.1038/sj.bdj.2014.907. PMID: 25342350.
5. Lockhart PB, Bolger AF, Papapanou PN, Osinbowale O, Trevisan M, Levison ME, Taubert KA, Newburger JW, Gornik HL, Gewitz MH, Wilson WR, Smith SC Jr, Baddour LM; American Heart Association Rheumatic Fever, Endocarditis, and Kawasaki Disease Committee of the Council on Cardiovascular Disease in the Young, Council on Epidemiology and Prevention, Council on Peripheral Vascular Disease, and Council on Clinical Cardiology. Periodontal disease and atherosclerotic vascular disease: does the evidence support an independent association?: a scientific statement from the American Heart Association. Circulation. 2012 May 22;125(20):2520-44. doi: 10.1161/CIR.0b013e31825719f3. Epub 2012 Apr 18. PMID: 22514251.
6. Chambers DW. Competency-based dental education in context. Eur J Dent Educ. 1998 Feb;2(1):8-13. doi: 10.1111/j.1600-0579.1998.tb00029.x. PMID: 9588957.
7. Koshy E, Nair KC, Dathan P, et al. Competency based dental education – a narrative review. Acta Sci Dent Sci. 2024;8(8):74-83. https://orcid.org/0000-0003-3114-3015
8. Chuenjitwongsa S, Oliver RG, Bullock AD. Competence, competency-based education, and undergraduate dental education: a discussion paper. Eur J Dent Educ. 2018 Feb;22(1):1-8. doi: 10.1111/eje.12213. Epub 2016 Jun 1. PMID: 27246501.
9. Mofidi A, Perez A, Kornerup I, Levin L, Ortiz S, Lai H, Green J, Kim S, Gibson MP. Dental Students' Knowledge, Confidence, Ability, and Self-Reported Difficulties in Periodontal Education: A Mixed Method Pilot Study. Dent J (Basel). 2022 Apr 6;10(4):63. doi: 10.3390/dj10040063. PMID: 35448057; PMCID: PMC9026102.
10. Yadadi SS, Tariq A, Salah F, Ahmed S, Riad S, Neel EAA, Mohammed MM, Shetty RM. Knowledge, awareness and perception of dental students about the world workshop classification of periodontal and peri-implant diseases and conditions 2017 - a questionnaire-based survey. BMC Oral Health. 2025 Apr 24;25(1):632. doi: 10.1186/s12903-025-05999-z. PMID: 40275245; PMCID: PMC12023697.
11. Lande A, Durge K, Rawat S, Reche A, Sonar PR. Perception of undergraduates in the field of periodontology. Cureus. 2023 Nov 5;15(11):e48308. doi:10.7759/cureus.48308.
12. Divya M, Esther Nalini H, Nityakala C, Sonika S, Vinoth Kumar S, Nivethitha S. Perception of periodontology among undergraduate dental students in Tamilnadu – A preliminary descriptive questionnaire survey. Int J Dent Med Sci Res. 2025;7(1):275–281.
13. Mofidi A, Perez A, Kornerup I, Levin L, Ortiz S, Lai H, et al. Dental students' knowledge, confidence, ability, and self-reported difficulties in periodontal education: a mixed method pilot study. Dent J (Basel). 2022 Apr 6;10(4):63. doi:10.3390/dj10040063.
14. Wathlan JA, Alqahtani H. Evaluating dental students' satisfaction in clinical Periodontics courses at KSAU-HS: a cross-sectional study. BMC Med Educ. 2025 Jan 27;25(1):128. doi: 10.1186/s12909-025-06720-y. PMID: 39871220; PMCID: PMC11770937.
15. Sanz M, Meyle J. Scope, competences, learning outcomes and methods of periodontal education within the undergraduate dental curriculum: a consensus report of the 1st European Workshop on Periodontal Education--position paper 2 and consensus view 2. Eur J Dent Educ. 2010 May;14Suppl 1:25-33. doi: 10.1111/j.1600-0579.2010.00621.x. PMID: 20415973.
16. Gürsoy M, Wilensky A, Claffey N, Herrera D, Preshaw PM, Sanz M, Schlagenhauf U, Trombelli L, Demirel K. Periodontal education and assessment in the undergraduate dental curriculum-A questionnaire-based survey in European countries. Eur J Dent Educ. 2018 Aug;22(3):e488-e499. doi: 10.1111/eje.12330. Epub 2018 Feb 20. PMID: 29460375.
17. Sanz M, Figuero E, Herrera D. Education in Periodontology: The Past, the Present, and the Future. J Periodontal Res. 2025 Apr;60(4):291-299. doi: 10.1111/jre.13417. Epub 2025 May 26. PMID: 40420527; PMCID: PMC12139694.

Research Article

Awareness and Knowledge of the Role of Probiotics and Prebiotics in Periodontal Health Among Undergraduate Dental Students: A Cross-Sectional Survey

Nandini Metaliya, Akshaya Banodkar, Rajesh Gaikwad, Gulnar Sethna, Madhumitha C, Akhrienuo Kiso

Department of Periodontology, Government Dental College and Hosital, Mumbai (Maharashtra)

ABSTRACT:

Background: Periodontal diseases are highly prevalent and biologically based adjuncts such as probiotics and prebiotics are gaining interest as potential modulators of the oral microbiome. This cross-sectional, questionnaire-based survey aimed to assess the awareness, knowledge and attitudes regarding probiotics and prebiotics in periodontal health among undergraduate dental students.

Materials & Methods: A total of 236 students from first year to internship completed a validated, self-administered questionnaire comprising items on demographics, awareness and knowledge of probiotics and prebiotics, and perceptions about the need for scientific evidence.

Results: Most respondents had heard of probiotics (85.2%) and correctly defined them as live microorganisms that confer health benefits (79.2%). Over half recognised combined antimicrobial mechanisms and multiple delivery forms, and the majority acknowledged broad oral benefits and common probiotic food sources. However, only 42.4% correctly defined prebiotics as non-digestible fibres or carbohydrates, and uncertainty regarding their systemic effects remained considerable despite better recognition of dietary sources and commonly used oligosaccharides. Overall, 80.1% of students considered scientific evidence to be very or somewhat important for integrating probiotics and prebiotics into periodontal care.

Conclusion: The findings indicate that while basic awareness and attitudes towards probiotics are favourable, important gaps persist in detailed mechanistic understanding and in knowledge of prebiotics. Targeted curricular reinforcement on host–microbiome interactions and biologically based adjuncts is warranted to support evidence-based periodontal practice.

KEY WORDS: Probiotics; Prebiotics; Periodontal health; Dental students; Awareness.

Address for correspondence : Dr. Nandini Metaliya, 215 Department of Periodontology, Government Dental College and Hospital, Mumbai- 400001 (Maharashtra) , India, E-mail: nandinimetaliya19@gmail.com

Submitted: 17.07.2025, **Accepted:** 06.12.2025, **Published:** 18.12.2025

INTRODUCTION:

Periodontal diseases are among the most prevalent chronic inflammatory conditions affecting the oral cavity and are a major cause of tooth loss worldwide[1,2]. They arise from a complex interplay between dysbiotic dental biofilms and the host immune response, influenced by behavioural, systemic and environmental risk factors[3]. Conventional periodontal therapy has largely focused on mechanical plaque control and, where indicated, adjunctive antimicrobial agents[4]. However, concerns regarding antimicrobial resistance, disruption of the commensal microbiota and patient compliance have prompted increasing interest in biologically based strategies that modulate, rather

Access this article online

Quick Response Code:	Website: www.pjsr.org
	DOI: https://doi.org/10.5281/zenodo.17975212

This is an open access journal, and articles are distributed under the terms of the Creative Commons Attribution-Non Commercial ShareALike 4.0 License, which allows others to remix, tweak, and build upon the work non-commercially, as long as appropriate credit is given and the new creations are licensed under the identical terms.

For reprints contact: editor.pjsr@peoplesuniversity.edu.in

How to cite this article: Metaliya N, Banodkar A, Gaikwad R, Sethna G, Madhumitha C, Kiso A. Awareness and Knowledge of the Role of Probiotics and Prebiotics in Periodontal Health Among Undergraduate Dental Students: A Cross-Sectional Survey . PJSR. 2025;18(2):11-20.

than eradicate, the microbial ecosystem[5].

In this context, probiotics and prebiotics have emerged as promising adjuncts in oral healthcare. Probiotics are defined as live microorganisms which, when administered in adequate amounts, confer a health benefit on the host[6,7]. In the oral cavity, specific probiotic strains have been shown to compete with pathogenic species, alter biofilm composition, produce antimicrobial substances such as organic acids, hydrogen peroxide and bacteriocins, and modulate local immune responses[8,9]. Clinical studies suggest that probiotic formulations delivered via tablets, lozenges, chewing gums or dairy products may reduce plaque accumulation, gingival inflammation and halitosis, and support periodontal therapy outcomes[8,9]. Prebiotics, on the other hand, are non-digestible food components that selectively stimulate the growth and activity of beneficial microorganisms[10,11]. Although their role is better established in gastrointestinal health, interest is growing in their potential systemic and oral benefits, including the creation of a more favourable ecological niche for health-associated bacteria[11,12].

The successful integration of probiotics and prebiotics into periodontal care depends not only on the strength of scientific evidence, but also on the awareness, understanding and attitudes of future dental practitioners. Undergraduate dental students represent a critical group, as their knowledge and perceptions will shape their future clinical decision-making, patient counselling and acceptance of emerging biologically based therapies. Surveys from different settings indicate that, while many dental students and trainees have heard of probiotics and recognise their general health benefits, knowledge of specific indications, strains, delivery systems and the concept of prebiotics remains variable and often incomplete[13–16]. Yet, despite expanding literature on probiotics in dentistry, there appears to be limited information on how well dental students understand the concepts of probiotics, prebiotics and their application to periodontal health, and on where they obtain such information[13–16]. Against this background, the present study was undertaken to explore the awareness, knowledge and perceptions regarding the role of probiotics and prebiotics in periodontal health among undergraduate dental students. Understanding these baseline levels of awareness is essential to identify educational gaps and to inform curriculum planning and targeted teaching strategies that support evidence-based periodontal care.

MATERIALS & METHODS:

Study design and setting: This was a descriptive, cross-sectional, questionnaire-based survey conducted among undergraduate dental students enrolled in a dental teaching institution. The study was designed to assess awareness, knowledge and perceptions regarding the role of probiotics and prebiotics in periodontal health. Data were collected over a defined period during regular academic sessions to ensure that students from all years of study had an opportunity to participate.

Study population and sampling: The target population comprised Bachelor of Dental Surgery (BDS) students from first year to internship. All students who were present on the days of data collection, met the eligibility criteria and provided consent were invited to participate. Postgraduate students, teaching staff and auxiliary personnel were excluded. Incomplete or illegibly filled questionnaires were also excluded from analysis. A total of 236 undergraduate students with adequately completed questionnaires were included in the final dataset.

Development of the questionnaire: The structured questionnaire was developed after a review of the existing literature on probiotics, prebiotics and their applications in periodontal and general oral health, as well as previously used instruments assessing awareness of probiotics among dental professionals and students. The draft tool comprised four sections: (i) demographic details (age, gender, year of study), (ii) awareness and basic knowledge of probiotics, (iii) knowledge of prebiotics and their systemic and dietary aspects, and (iv) attitudes towards the importance of scientific evidence and open-ended comments. Items were primarily closed-ended, with single-best-answer multiple-choice questions and selected multiple-response items, along with one open-ended question to capture additional comments or suggestions.

Content validity was established by a panel of subject experts from periodontology and oral microbiology, who evaluated each item for clarity, relevance and appropriateness. Based on their feedback, minor modifications were made to wording and sequencing to improve comprehensibility and face validity. The questionnaire was then pilot-tested on a small group of undergraduate students who were not included in the main study, to ensure that item wording was clear and that the average completion time was acceptable. No major changes were required after pilot testing.

Data collection procedure: Data collection was carried out in classroom settings at the end of scheduled

lectures or clinical postings to minimise disruption of academic activities. The purpose of the study was explained to the students, and they were assured that participation was voluntary, responses would remain anonymous, and non-participation would not affect their academic standing. Students who agreed to participate provided informed consent and were given the self-administered paper questionnaire. They were instructed not to discuss their answers with peers while completing the form. The average time required to complete the questionnaire was approximately 10–15 minutes. Completed questionnaires were collected immediately to avoid loss or exchange of forms. Each questionnaire was checked for completeness before data entry.

Ethical considerations: The study protocol was reviewed and approved by the Institutional Ethics Committee of the host institution prior to commencement. All procedures adhered to the ethical principles of the Declaration of Helsinki. Participation was entirely voluntary, written informed consent was obtained from all respondents, and confidentiality was maintained by avoiding collection of personally identifying information. Data were stored securely and used solely for research and academic purposes.

***Statistical analysis*:** Data from the completed questionnaires were coded and entered into a spreadsheet and then imported into a statistical software package for analysis (e.g. IBM SPSS Statistics). Descriptive statistics were used to summarise the data: categorical variables were expressed as frequencies and percentages. Where applicable, associations between demographic variables (such as age group, gender and year of study) and key awareness/knowledge items were evaluated using the Chi-square test. A p-value of <0.05 was considered statistically significant.

RESULTS:

Participant characteristics: A total of 236 undergraduate dental students participated in the survey. The majority of respondents were in the 21–23 year age group, with smaller proportions in the 18–20 and 24–26-year categories, and very few students aged 27 years and above. Most participants were female, with males forming roughly one-quarter of the sample and only a small fraction identifying as other gender or preferring not to disclose. With respect to academic level, second-year students constituted the largest group, followed by third-year and final-year students, while first-year students and interns represented relatively smaller proportions of the cohort. This distribution reflects a broad representation across the undergraduate years, with a slight predominance of students in the early clinical phase of training Table 1.

Awareness and exposure to probiotics:

Most undergraduate dental students reported prior awareness of probiotics, with over four-fifths indicating that they had heard of probiotics before. However, less than half of the respondents had ever been advised by a healthcare professional to use probiotics specifically for improving gum health. Around three-fifths believed that probiotics could help

Table 1: Demographic characteristics of the study participants (n = 236).

Variable	Category	Frequency (n)	Percentage (%)
Age (years)	18–20	55	23.3
	21–23	149	63.1
	24–26	30	12.7
	27 and above	2	0.8
Gender	Male	59	25.0
	Female	173	73.3
	Other	3	1.3
	Prefer not to answer	1	0.4
Year of study*	First year	16	8
	Second year	85	36.0
	Third year	66	28.0
	Final year	49	20.8
	Internship	16	6.8

*Totals for year of study may be slightly lower than 236 due to missing responses and rounding.

Table 2: Awareness, exposure and sources of information regarding probiotics among undergraduate dental students (n = 236).

Domain	Item/option	Response category	Frequency (n)	Percentage (%)	*p-value**
Awareness / exposure	Have you heard of probiotics before?	Yes	201	85.2	0.004*
	Have you ever been advised by a healthcare professional to use probiotics for improving your gum health?	Yes	99	41.9	0.541 (NS)
	Do you think probiotics can help prevent or treat gum diseases such as gingivitis or periodontitis?	Yes	144	61.0	0.892 (NS)
Source of information	Social media (Instagram, YouTube, television)	–	88	37.3	
	Family/friends	–	34	14.4	
	University courses	–	64	27.1	
	Health professionals (dentist, doctor)	–	44	18.6	

*$p < 0.05$ considered statistically significant; NS, non-significant ($p > 0.05$).

in the prevention or treatment of gingival and periodontal diseases, reflecting a generally positive perception of their potential clinical role. When asked about their initial source of information, social media emerged as the most common channel, followed by university courses, health professionals and, to a lesser extent, family and friends. This pattern suggests that while formal dental education contributes to awareness, a substantial proportion of students are first exposed to the concept of probiotics through informal, non-academic platforms Table 2.

Knowledge regarding probiotics: Overall, students demonstrated relatively good conceptual knowledge of probiotics. The majority correctly identified probiotics as live microorganisms that provide health benefits, while only a small proportion considered them merely as types of bacteria, medications for digestive issues or were unsure of the definition. When asked about antimicrobial substances produced by probiotics, more than half of the respondents recognised that probiotics generate a combination of organic acids, hydrogen peroxide and bacteriocins, although a notable minority selected only one of these options or indicated none. Awareness of different delivery forms was moderate: while the largest group correctly acknowledged that probiotics are available across all listed formats, including tablets, chewing gums, toothpaste, lozenges, gummies and mouthwash, a substantial number of students were aware of only a subset of these forms or reported no awareness of any, and a small group did not respond. These findings suggest that although the basic concept and mechanisms of probiotics are reasonably well understood, there remain gaps in detailed practical knowledge regarding their various formulations and routes of administration Table 3.

Knowledge of probiotic benefits, food sources, species and side effects: Students generally demonstrated favourable perceptions of the potential benefits of probiotics for oral health. More than half of the respondents believed that probiotics could simultaneously reduce gum inflammation, prevent tooth decay, improve overall immune function and freshen breath, whereas smaller proportions focused on only one cluster of benefits or were uncertain. Similarly, a majority correctly associated probiotics with a broad range of fermented foods, indicating an awareness that probiotic microorganisms are commonly present in multiple dietary sources rather than restricted to a single food group.

With regard to microbiological knowledge, many students recognised specific probiotic species

Table 3: Knowledge of concept, antimicrobial mechanisms and delivery forms of probiotics among undergraduate dental students (n = 236).

Domain	Question	Response option	Frequency (n)	Percentage (%)
Concept of probiotics	How would you define probiotics?	Live microorganisms that provide health benefits	187	79.2
		Only types of bacteria	14	5.9
		Medications for digestive issues	18	7.6
		I don't know	17	7.2
Antimicrobial mechanisms	What are the antimicrobial substances produced by probiotics ?	Organic acids	49	20.8
		Hydrogen peroxide and bacteriocins	41	17.4
		All of the above	125	53.0
		None of the above	17	7.2
Delivery forms	What forms of probiotics are you aware of?	Tablets, chewing gums, toothpaste	35	14.8
		Lozenges, gummies, mouthwash	44	18.6
		All of the above	99	41.9
		None of the above	46	19.5
		No response	12	5.1

such as *Lactobacillus casei*, *Lactobacillus reuteri*, *Streptococcus salivarius* and *Bifidobacterium* spp., and a considerable proportion correctly identified that all of these could be involved in probiotic formulations. However, a notable fraction selected only a subset of these species or reported no awareness, suggesting that detailed understanding of strain diversity remains incomplete. Awareness of potential adverse effects was moderate: while nearly half of the respondents acknowledged that probiotics may be associated with gastrointestinal symptoms such as diarrhoea, bloating, discomfort and occasional allergic reactions, a sizeable group either identified only part of this spectrum or were unsure. These findings indicate that, although students broadly appreciate the beneficial role of probiotics in oral and systemic health, there are areas where more nuanced teaching on specific strains and safety considerations could be valuable Table 4.

Knowledge regarding prebiotics: Compared with probiotics, students' understanding of prebiotics appeared more limited and variable. Fewer than half of the respondents correctly identified a prebiotic as a non-digestible special form of fibre or carbohydrate that beneficially affects the host, while a notable proportion misinterpreted prebiotics as live microorganisms, a type of probiotic, or reported that they were not sure. Nonetheless, many students showed some awareness of the broader health implications of prebiotics, with almost half recognising that they may contribute both to lowering blood cholesterol and reducing the risk of colorectal cancer, although a substantial minority selected only one of these benefits or expressed uncertainty.

Knowledge of dietary sources was relatively better developed: the majority of participants correctly acknowledged that commonly consumed Indian foods such as oats, whole wheat flour, green banana, cooked rice and maize flour may serve as prebiotic sources, while only a small fraction believed that none of these foods were relevant. When asked about commonly used prebiotic forms, more than half of the students recognised that fructo-oligosaccharides, galacto-oligosaccharides and trans-galacto-oligosaccharides are all employed as prebiotics, although a smaller proportion identified only one specific class. Overall, these findings suggest that while students have some familiarity with prebiotic-related concepts, particularly in relation to food sources and oligosaccharide forms, there remain important gaps in their conceptual and

Table 4: Knowledge of probiotic benefits, dietary sources, bacterial species and side effects among undergraduate dental students (n = 236).

Domain	Question	Response option	Frequency (n)	Percentage (%)
Perceived benefits	Which of the following do you believe are the potential benefits of probiotics for oral health?	Reduce gum inflammation and prevent tooth decay	51	21.6
		Improve overall immune system function and freshen breath	47	19.9
		All of the above	133	56.4
		Not sure	5	2.1
Dietary sources	Which of the following foods do you associate with probiotics?	Yogurt, sauerkraut	74	31.4
		Kefir, cheese	22	9.3
		All of the above	124	52.5
		None of the above	11	4.7
Bacterial species	According to you, which are the possible bacterial species involved in probiotics?	*Lactobacillus casei* and *Lactobacillus reuteri*	106	44.9
		Streptococcus salivarius and *Bifidobacterium* species	30	12.7
		All of the above	90	38.1
		None of the above	10	4.2
Side effects	What are the possible side effects of probiotics?	Diarrhoea and bloating	29	12.3
		Discomfort in gastrointestinal tract and allergic reactions	50	21.2
		All of the above	104	44.1
		Not sure	48	20.3

mechanistic understanding that warrant targeted curricular emphasis Table 5.

Attitudes towards evidence-based use of probiotics and prebiotics: Students generally expressed a positive attitude towards the need for scientific validation of probiotics and prebiotics in periodontal health. Nearly half of the respondents considered it very important that the use of these agents be supported by robust scientific evidence, and approximately one-third regarded such evidence as somewhat important. Only a small minority felt that scientific evidence was not important, while a comparable proportion selected "others" and provided additional comments, reflecting nuanced views or conditional acceptance. Overall, this pattern suggests that most undergraduate dental students value an evidence-based approach and are receptive to integrating probiotics and prebiotics into

Table 5: Knowledge of prebiotic definition, systemic benefits, dietary sources and commonly used forms among undergraduate dental students (n = 236).

Domain	Question	Response option	Frequency (n)	Percentage (%)
Concept of prebiotics	What do you understand by a prebiotic ?	Non-digestible special form of fibre/carbohydrate	100	42.4
		Live microorganism	43	18.2
		A type of probiotic	34	14.4
		Not sure	59	25.0
Systemic benefits	What do you think are the systemic benefits of prebiotics?	Reduction in blood cholesterol levels	28	11.9
		Reduced risk of colorectal cancer	41	17.4
		All of the above	110	46.6
		Not sure	57	24.2
Dietary sources	What are the possible Indian dietary sources of prebiotics?	Oats, whole wheat flour, green banana	28	11.9
		Cooked rice, maize flour	34	14.4
		Both a and b	151	64.0
		None	23	9.7
Common prebiotic forms	Which are the most commonly used prebiotic forms?	Fructo-oligosaccharides (FOS)	19	8.1
		Galacto-oligosaccharides (GOS)	40	16.9
		Trans -galacto-oligosaccharides (TOS)	29	12.3
		All of the above	134	56.8

Table 6: Attitudes towards the importance of scientific evidence for the use of probiotics and prebiotics in periodontal health (n = 236).

Question	Response option	Frequency (n)	Percentage (%)
How important is it to have scientific evidence supporting the use of probiotics and prebiotics for improving periodontal health?	Very important	112	47.5
	Somewhat important	77	32.6
	Not important	23	9.7
	Others	24	10.2

periodontal care, provided that their efficacy and safety are substantiated by high-quality research Table 6.

DISCUSSION:

The present survey provides an overview of undergraduate dental students' awareness and knowledge regarding probiotics and prebiotics in the context of periodontal health. Overall, the findings indicate a high level of basic awareness about probiotics, with the majority of students able to correctly define them as live microorganisms that confer health benefits and to recognise their broad oral-health–related advantages. This pattern is consistent with previous surveys among dental students and practitioners, which have reported that between two-thirds and over four-fifths of respondents are familiar with the term “probiotics” and acknowledge their

general health benefits[17–20]. Studies from India and elsewhere have similarly shown that most dental students recognise probiotics as live microorganisms and believe they can improve health, although detailed knowledge scores are often only in the "fair" range rather than excellent[17–19,21]. Our findings thus align with earlier work by Santhanam et al. among dental practitioners in Puducherry, where the majority demonstrated acceptable or higher levels of knowledge, suggesting that basic conceptual understanding of probiotics is now reasonably well established in the dental community[20].

In the present study, students also demonstrated a good grasp of the potential benefits and dietary sources of probiotics. Most respondents recognised that probiotics could contribute simultaneously to reducing gingival inflammation, preventing dental caries, supporting immune function and improving breath, and were aware of multiple fermented foods as common probiotic carriers. Similar trends have been reported by Philip et al. and others, where large proportions of dental students agreed that probiotics improve health and expressed willingness to use them if recommended by professionals[17,21]. However, our data also reveal that knowledge becomes less robust when more detailed or mechanistic aspects are considered. Only around half of the students correctly identified all major antimicrobial substances produced by probiotics, and a substantial minority were unsure about specific probiotic species or potential adverse effects. This mirrors the observations of Babina et al., who found that, although attitudes toward probiotics were highly positive among dental students and teachers, detailed factual knowledge remained only moderate, underscoring the need for more structured teaching on strain-specific actions and safety[19].

The relatively lower level of understanding observed for prebiotics in this cohort is notable and has important curricular implications. Less than half of the students correctly defined prebiotics as non-digestible fibres or carbohydrates that beneficially affect the host, and many were uncertain about their systemic benefits, despite demonstrating better recognition of dietary sources and commonly used oligosaccharide forms. Recent KAP studies among dental undergraduates and dental trainees have similarly reported that, while awareness of probiotics is high, awareness and understanding of prebiotics remain limited in both groups[18,22]. This imbalance suggests that educational efforts in dentistry have so far focused more on probiotics as "active agents" than on the complementary concept of prebiotics as substrates that selectively favour beneficial microbiota. Given emerging evidence that both probiotics and prebiotic substrates can modulate the oral and gut microbiomes, influence host immune responses and potentially support periodontal therapy, this gap warrants attention[23,24].

The generally positive attitude towards evidence-based use of probiotics and prebiotics observed in this study is encouraging. Nearly four-fifths of the respondents considered scientific evidence to be very or somewhat important for the adoption of these agents in periodontal care, echoing earlier findings that dental students, postgraduates and academics are willing to recommend probiotics when their benefits are supported by peer-reviewed literature[18,19,22]. This mindset is particularly relevant in light of recent systematic reviews and meta-analyses, which, while suggesting that certain probiotic formulations may improve clinical periodontal parameters when used as adjuncts to mechanical therapy, also highlight heterogeneity across trials and the need for cautious interpretation[23,25,26]. Integrating up-to-date evidence on host–microbiome interactions and biologically based therapeutics into undergraduate curricula could therefore foster critical appraisal skills and prevent uncritical uptake of commercially driven claims.

This study has some limitations that should be considered when interpreting the findings. It was conducted in a single institution with a cross-sectional design, which may limit the generalisability of the results to other dental schools or regions. The use of a self-administered questionnaire introduces the possibility of social desirability and recall bias, and the assessment focused on self-reported knowledge rather than objective testing of competence or translation into clinical practice. In addition, while the questionnaire was content-validated, more extensive psychometric evaluation (for example, reliability testing and factor analysis) was not undertaken. Future research could involve multi-centre studies with larger and more diverse samples, incorporate longitudinal designs to assess the impact of targeted educational interventions on knowledge and behaviour, and explore how enhanced understanding of probiotics and prebiotics influences actual clinical decision-making and patient counselling in periodontal care.

CONCLUSION:

The present study shows that undergraduate dental students possess good basic awareness and generally favourable perceptions of probiotics in relation to periodontal health, but their understanding of prebiotics and more detailed mechanistic and strain-

specific aspects remains limited. Social media and university teaching emerged as key sources of information, and most students expressed a strong preference for evidence-based use of probiotics and prebiotics in clinical practice. These findings highlight the need to strengthen and formalise curricular content on host–microbiome interactions, probiotics and prebiotics, with emphasis on indications, limitations and safety. Enhancing this knowledge at the undergraduate level may ultimately support more rational, evidence-based integration of biologically based adjuncts into periodontal care.

Financial Support and Sponsorship
Nil.

Conflicts of Interest
There are no conflicts of interest.

REFERENCES:

1. Tonetti MS, Jepsen S, Jin L, Otomo-Corgel J. Impact of the global burden of periodontal diseases on health, nutrition and wellbeing: A call for global action. J ClinPeriodontol. 2017 May;44(5):456-62. doi:10.1111/jcpe.12732.
2. Hoare A, Soto C, Rojas-Celis V, Bravo D. Chronic inflammation as a link between periodontitis and carcinogenesis. Mediators Inflamm. 2019;2019:1029857. doi:10.1155/2019/1029857.
3. Cugini C, Ramasubbu N, Tsiagbe VK, Fine DH. Dysbiosis from a microbial and host perspective relative to periodontitis. Front Microbiol. 2021 Mar 11;12:617485. doi:10.3389/fmicb.2021.617485.
4. Shaddox LM, Walker CB. Treating chronic periodontitis: current status, challenges, and future directions. ClinCosmetInvestig Dent. 2010 Aug 11;2:79-91. doi:10.2147/CCIDEN.S8520.
5. Ng E, Tay JRH, Boey SK, Laine ML, Ivanovski S, Seneviratne CJ. Antibiotic resistance in the microbiota of periodontitis patients: an update of current findings. Crit Rev Microbiol. 2024 May;50(3):329-40. doi:10.1080/1040841X.2023.2197481.
6. FAO/WHO. Guidelines for the evaluation of probiotics in food. Report of a Joint FAO/WHO Working Group on Drafting Guidelines for the Evaluation of Probiotics in Food. London (ON): FAO/WHO; 2002.
7. Binda S, Hill C, Johansen E, Obis D, Pot B, Sanders ME, et al. Criteria to qualify microorganisms as "probiotic" in foods and dietary supplements. Front Microbiol. 2020 Jul 10;11:1662. doi:10.3389/fmicb.2020.01662.
8. Hu D, Chen L, Bai Y, Huang D. Clinical efficacy of probiotics as an adjunctive therapy to scaling and root planing in the treatment of chronic periodontitis: A systematic review and meta-analysis. J Evid Based Dent Pract. 2021 Sep;21(3):101547. doi:10.1016/j.jebdp.2021.101547.
9. Hardan L, Bourgi R, Cuevas-Suárez CE, Zarow M, Kharouf N, Mancino D, et al. The use of probiotics as adjuvant therapy of periodontal disease: A systematic review and meta-analysis. Pharmaceutics. 2022 May 9;14(5):1017. doi:10.3390/pharmaceutics14051017.
10. Gibson GR, Roberfroid MB. Dietary modulation of the human colonic microbiota: Introducing the concept of prebiotics. J Nutr. 1995 Jun;125(6):1401-12. doi:10.1093/jn/125.6.1401.
11. Gibson GR, Hutkins R, Sanders ME, Prescott SL, Reimer RA, Salminen SJ, et al. The International Scientific Association for Probiotics and Prebiotics (ISAPP) consensus statement on the definition and scope of prebiotics. Nat Rev GastroenterolHepatol. 2017 Aug;14(8):491-502. doi:10.1038/nrgastro.2017.75.
12. Hutkins RW, Krumbeck JA, Bindels LB, Cani PD, Fahey G Jr, Goh YJ, et al. Prebiotics: Why definitions matter. CurrOpinBiotechnol. 2016 Apr;37:1-7. doi:10.1016/j.copbio.2015.09.001.
13. Patait MR, Bhatia S, Patait P, Kulkarni P, Tambe V, Agrawal R. Assessment of knowledge and awareness of probiotics among the dental post-graduate students – A questionnaire study. Ann Maxillofac Res. 2022;12(4):1-6.
14. Babina K, Salikhova D, Polyakova M, Zaytsev A, Egiazaryan A, Novozhilova N. Knowledge and attitude towards probiotics among dental students and teachers: A cross-sectional survey. Dent J (Basel). 2023 May;11(5):119. doi:10.3390/dj11050119.
15. Abdul Saheer P, Philip C, Sreedhar G, Mahesh PC, Ashique MP, Shanila AM. Knowledge and awareness of probiotics among the dental students in Thodupuzha – a questionnaire study. Indian J Appl Res. 2019 Mar;9(3):1-3. doi:10.36106/ijar.
16. Upasana K, Sandhu R, Kataria P, Sinha A, Vatsa R, Parveen N. Evaluating the awareness and knowledge about probiotics in postgraduate students of an Indian dental college. J Pharm Bioallied Sci. 2024 Dec;16(Suppl 4):S3956-S3958. doi:10.4103/jpbs.jpbs_1020_24.
17. Krishnan L, Poorni S, Nivedhitha MS, Srinivasan MR. Knowledge, attitude, and practice of probiotics for oral health among dental students: A cross-sectional study. *J Indian Assoc Public Health Dent.* 2022;20(3):230-235. DOI:10.4103/jiaphd.jiaphd_23_22
18. Rajeev G, Jacob A, Santhosh S, Babu J, Thomas B. A survey of the knowledge, attitude, and practice of using

probiotics for oral health among dental students in Kerala. *Int J Community Med Public Health.* 2024;11(4):1538-1542. https://doi.org/10.18231/j.jds.81348.1759128217

19. Babina K, Salikhova D, Polyakova M, Zaytsev A, Egiazaryan A, Novozhilova N. Knowledge and Attitude towards Probiotics among Dental Students and Teachers: A Cross-Sectional Survey. Dent J (Basel). 2023 May 2;11(5):119. doi: 10.3390/dj11050119. PMID: 37232770; PMCID: PMC10217036.
20. Santhanam V, Devi M, Aravindan R, Suganya R, Aroumugam S, Babu MA. Awareness of probiotics among dental practitioners of Puducherry-A cross-sectional questionnaire study. J Oral Maxillofac Pathol. 2022 Oct-Dec;26(4):597. doi: 10.4103/jomfp.jomfp_422_21. Epub 2022 Dec 22. PMID: 37082053; PMCID: PMC10112070.
21. Philip C, Sreedhar G, Muhammed A, Majid SA. Knowledge and awareness of probiotics among the dental students in Thodupuzha – A questionnaire study. *Indian J Appl Res.* 2019;9(3):32-34.
22. Raja N, Ganesan A, Swathi KV, Kannan A, Lakshmi KC. Awareness of prebiotics and probiotics in oral lesions among dental postgraduates – A questionnaire-based study. *Biomedicine (India).* 2023;43(3):921-924. https://doi.org/10.51248/.v43i3.2716
23. Gheisary Z, Mahmood R, HarriShivanantham A, Liu J, Lieffers JRL, Papagerakis P, Papagerakis S. The Clinical, Microbiological, and Immunological Effects of Probiotic Supplementation on Prevention and Treatment of Periodontal Diseases: A Systematic Review and Meta-Analysis. Nutrients. 2022 Feb 28;14(5):1036. doi: 10.3390/nu14051036. PMID: 35268009; PMCID: PMC8912513.
24. Chugh P, Dutt R, Sharma A, Bhagat N, Dhar MS. A critical appraisal of the effects of probiotics on oral health. *J Funct Foods.* 2020;70:103985. https://doi.org/10.1016/j.jff.2020.103985
25. Hardan L, Bourgi R, Cuevas-Suárez CE, Flores-Rodríguez M, Omaña-Covarrubias A, Nicastro M, Lazarescu F, Zarow M, Monteiro P, Jakubowicz N, Proc P, Lukomska-Szymanska M. The Use of Probiotics as Adjuvant Therapy of Periodontal Treatment: A Systematic Review and Meta-Analysis of Clinical Trials. Pharmaceutics. 2022 May 9;14(5):1017. doi: 10.3390/pharmaceutics14051017. PMID: 35631603; PMCID: PMC9143599.
26. Tan J, O'Connor A, Wang L, et al. The impacts of probiotics supplementation on the treatment of periodontitis: An umbrella meta-analysis. *Nutr Rev.* 2025; published online ahead of print. doi:10.1093/nutrit/nuae190.

Research Article

Assessment of Modifiable Risk Factors Among Type 2 Diabetes Mellitus Patients

Manu Gupta, Afreen Ali, Rajkumar Upadhyay, OP Nayak
Department of Internal Medicine, People's College of Medical Sciences and Research Centre, Bhanpur, Bhopal (Madhya Pradesh)

ABSTRACT:

Background: With the evidences available in the ancient literature of Sanskrit, diabetes mellitus (DM) could possibly be termed as 'honey-urine disease' which is associated with gross emaciation and wasting. DM is the most commonly referred metabolic disorder that affect majority of the people globally. Hence, the present study was conducted for assessing modifiable risk factors among type 2 DM patients.

Materials & Methods: Patients were evaluated by history taking, examination and performing relevant investigations. For each subject a separate clinical proforma, incorporating detailed history with duration, clinical examination and relevant information was used. Lipid profile was evaluated. Fasting and PPG were defined as value of plasma glucose measured after overnight (8–12 h) fasting and after 2 h of meals respectively. Pharmacological intervention is required in clients with HbA1c levels greater than 7.0%. The HbA1c test is recommended for the diagnosis of diabetes mellitus and can also guide appropriate ongoing management of patients with diabetes.

Results: 71.5% of the subjects were non-smokers (143 subjects) while 15.5% were smokers (31 subjects) and 13.0% had quit smoking (26 subjects).58.0% of the subjects did not use tobacco (116 subjects) while 31.0% used tobacco (62 subjects) and 11.0% had quit using tobacco (22 subjects).75.0% of the subjects did not consume alcohol (150 subjects) while 8.5% consumed alcohol (17 subjects) and 16.5% had quit consuming alcohol (33 subjects).49.0% of the subjects were vegetarians (98 subjects) while 46.0% were non-vegetarians (92 subjects) and 5.0% had a mixed diet (10 subjects).48.5% of the subjects engaged in 50-100 minutes of physical activity per week (97 subjects) while 24.0% engaged in less than 50 minutes per week (48 subjects) The least number of subjects reported no physical activity (1 subject, 0.5%).53.0% of subjects had low density lipoprotein (LDL) dyslipidaemia (106 subjects) while 47.0% had normal LDL levels (94 subjects) The highest dyslipidaemia was observed in triglyceride (TG) (45.0%) and the lowest in TC (35.0%).

Conclusion: Our study's findings unequivocally demonstrate that HbA1c, the established benchmark for evaluating glycemic control, exhibits a robust association with the lipid profile. The study among subjects with HbA1c levels exhibited a favorable lipid profile of TG , total cholesterol (TC), LDL and high density lipoprotein (HDL). These findings suggest a positive correlation between normoglycemic HbA1c levels and a desirable lipid profile, indicative of reduced risk. This characteristic renders it an optimal indicator for predicting dyslipidemia in individuals with type 2 diabetes mellitus.

KEY WORDS: Risk factor, Diabetes mellitus, Diabetes Mellitus, Lipid, Blood sugar

Address for correspondence : Dr. Manu Gupta, PG, Resident, Department of Internal Medicine, People's College Medical Sciences and Research Centre, Bhanpur, Bhopal - 462037 (Madhya Pradesh), E-mail: manuguptabhopal@gmail.com
Submitted: 15.02.2025, **Accepted:** 25.11.2025, **Published:** 19.12.2025

INTRODUCTION:

With the evidences available in the ancient literature of Sanskrit, diabetes mellitus (DM) could possibly be termed as 'honey-urine disease' which is

Access this article online

Quick Response Code:	Website: www.pjsr.org
	DOI: https://doi.org/10.5281/zenodo.17984045

This is an open access journal, and articles are distributed under the terms of the Creative Commons Attribution-Non Commercial ShareALike 4.0 License, which allows others to remix, tweak, and build upon the work non-commercially, as long as appropriate credit is given and the new creations are licensed under the identical terms.
For reprints contact: editor.pjsr@peoplesuniversity.edu.in

How to cite this article: Gupta M, Ali A, Upadhyay R, OP Nayak. Assessment of Modifiable Risk Factors Among Type 2 Diabetes Mellitus Patients. PJSR. 2025;18(1):21-25.

associated with gross emaciation and wasting. DM is the most commonly referred metabolic disorder that affects majority of the people globally.[1]

It is the most frequent global endemic entity that has rapidly increasing prevalence in both the developing as well as the developed countries. DM is the group of metabolic diseases that is characterized by increase in the level of blood glucose that is most commonly results due to defects in the insulin secretion or insulin action or both. When considering the global arena, with the advent of newer discoveries in the field of DM, great hopes seems to be motivating and continued efforts in research have been shown to minimize morbidity and mortality rates.[2]

The metabolic dysregulations associated with the DM majorly causes various secondary pathophysiological changes in various organs and systems that greatly impose a huge burden on the individuals suffering from type – 2 DM. As per the available evidences, type – 2 is more commonly reported than type – 1 DM. Diabetes is greatly associated with the higher risk of morbidity and mortality due to cardiovascular diseases. Serum lipids are frequently abnormal and are more likely to be associated with the risk of developing coronary arterial disease. Worsening of the glycemic control majorly deteriorates lipids and lipoprotein abnormalities more specifically DM.[3,4]

A diabetic individual should be considered in good control of his/her blood glucose level when their fasting and post-prandial blood glucose (PPBG) values are as much close to those of the non-diabetic individuals as possible. This concept is actually difficult to be followed practically since even with quite good control of diabetes, fluctuations in the level of blood glucose might be marked exponentially from day to day and from hour to hour. Worsening of the glycemic control rapidly deteriorates lipid and lipoprotein abnormalities which suggests that dyslipidemia is secondary to insulin resistance and the unique combination of hyperlipidemia and dyslipidemia generates and enhanced atherogenic ambience within the circulation which then aggravates the progression to atherosclerosis. Atherosclerosis is characterized by the deposition of cholesterol from plasma lipoproteins onto the arterial walls.[5- 7] Hence, the present study was conducted for assessing modifiable risk factors among type 2 diabetes mellitus patients.

MATERIALS & METHODS:

The present study was conducted for assessing modifiable risk factors among T2DM patients. After obtaining approval from the institutional ethic committee, study was conducted in the department of internal medicine of our institute. The study sample constituted of 200 patients. A written informed consent was obtained from the patients who were enrolled in the present study. Patients willing to participate in the study were included. Patients with heavy debilitating diseases were excluded. Patients were evaluated by history taking, examination and performing relevant investigations. For each subject a separate clinical proforma incorporating detailed history with duration, clinical examination and relevant information. Lipid profile was evaluated. Fasting and PPBP were defined as value of plasma glucose measured after overnight (8–12 h) fasting and after 2 h of meals respectively. A random venous blood glucose or above 11.1 mmol/L (≥ 200 mg/dL) or a fasting blood glucose at or above 7 mmol/L (≥126 mg/dL) on two or more separate occasions indicates the patient is likely to have DM. Normal HbA1c: 3.5% to 5.6% or 15 to 42 mmol/mol. A HbA1c result >6.5% usually confirms the presence of DM. Pharmacological intervention is required in patients with HbA1c levels greater than 7.0%. The HbA1c is the recommended diagnostic test for DM and can also inform the appropriate ongoing management of the diabetic patient. The data was analyzed using IBM SPSS version 20 s/w. frequency distribution and cross tabulation was performed to prepare tables using PRISM and Microsoft Excel to prepare the tables. The quantitative data was expressed as mean and standard deviation. The categorical data was expressed as number and percentage. ANOVA using simple mean was performed to compare the mean whereas chi square test to compare the categorical data.

RESULTS:

71.5% of the subjects were non-smokers (143 subjects) while 15.5% were smokers (n=31) and 13.0% had quit smoking (n=26) (Table 1).

Table 1: Smoking.

Smoking	Frequency (n)	Percent
Yes	31	15.5
No	143	71.5
Left	26	13.0

Table 2: Smokeless Tobacco.

Tobacco use	Frequency (n)	Percent
Yes	62	31.0
No	116	58.0
Left	22	11.0

58.0% of the subjects did not use smokeless tobacco (n=116) while 31.0% used it (n=62) and 11.0% had quit the habit (n=22) (Table 2).75.0% of the subjects did not consume alcohol (n=150) while 8.5% consumed alcohol (n=17) and 16.5% had quit consuming alcohol (n=33) (Table 3). 49.0% of the subjects were vegetarians (98 subjects) while 46.0% were non-vegetarians (n=92) and 5.0% had a mixed diet (n=10) (Table 4). 48.5% of the subjects engaged in 50-100 minutes of physical activity per week (n=97) while 24.0% engaged in less than 50 minutes per week (48 subjects) The least number of subjects reported no physical activity (1 subject, 0.5%) (Table 5). 53.0% of subjects had LDL dyslipidaemia (106 subjects) while 47.0% had normal LDL levels (n=94). The highest dyslipidaemia was observed in TG (45.0%) and the lowest in TC (35.0%) (Table 6).

Table 3: Alcohol habit.

Alcohal Status	Frequency	Percent
Yes	17	8.5
No	150	75.0
Left	33	16.5

Table 4: Diet.

Diet	Frequency	Percent
Veg	98	49.0
Nonveg	92	46.0
Mixed	10	5

Table 5: Physical activity.

Physical Activity	Frequency	Percent
No activity	1	.5
<50 min / week	48	24.0
50-100 min / week	97	48.5
100-150 min / week	17	8.5
150 min / week	37	18.5

Table 6: Dyslipidemia.

	Frequency	Percent
	TC	
Dyslipiaemia	70	35.0
Normal	180	65.0
	TG	
Dyslipidaemia	90	45.0
Normal	110	55.0
	HDL	
Dyslipidaemia	92	46.0
Normal	108	54.0
	LDL	
Dyslipidaemia	106	53.0
Normal	94	47.0

DISCUSSION:

The prevalence of DM is on the rise, primarily due to changing lifestyles, excessive consumption of fats and refined sweets, and a lack of physical activity. Lifestyle changes are linked to insulin resistance, which is related with glucose intolerance, hyperinsulinemia, hypertension, dyslipidemia, and visceral obesity (also known as apple-shaped obesity). These conditions increase the risk of both microvascular and macrovascular diseases, as well as complications. This is associated with a high prevalence of cardiovascular disease. The quantity of LDL receptors rises in response to an increase in insulin levels. Consequently, a decrease in insulin levels leads to a reduction in LDL receptor levels, resulting in elevated levels of LDL cholesterol in individuals with T2DM. Dyslipidemia in T2DM is a controllable risk factor for cardiovascular disease, as it speeds up the advancement of atherosclerosis. HbA1c level is a more reliable measure for assessing the mean blood glucose level during a 3-month period. To make a timely and appropriate decision, it is crucial to assess the lipid profile of patients with T2DM.[8-10]

Out of the total respondents, 71.5% were categorized as non-smokers, 15.5% were smokers, and 13.0% had successfully stopped smoking. The act of smoking cigarettes is directly linked to the occurrence of DM.[11] Smoking has the potential to disrupt the balance of glucose in the body and may also impact the concentration of HbA1c. Smoking-induced oxidative stress might potentially impact blood glucose levels and disrupt the body's ability to regulate blood glucose, leading to insulin resistance.[12] However, no such findings were seen in our study. In the present study 58.0% subjects did not use tobacco, whereas 31.0% subjects used tobacco and 11.0% had stopped using tobacco. 75.0% of the subjects did not consume alcohol while 8.5% consumed alcohol and 16.5% had quit consuming alcohol. Regular alcohol consumption has a variety of consequences on blood lipid levels. Drinkers tend to have higher levels of HDL-C and triglycerides compared to non-drinkers, but their levels of LDL-C are lower.[13]

In our study we found that 49.0% of the subjects were vegetarians while 46.0% were non-vegetarians and 5.0% had a mixed diet. We found that 48.5% of the subjects engaged in 50-100 minutes of physical activity per week while 24.0% engaged in less than 50 minutes per week 48.5% of the subjects engaged in 50-100 minutes of physical activity per week while 24.0% engaged in less than 50 minutes per

week. Modifications in diet and physical activity are regarded as the initial treatment approach for those with prediabetes.[14] Pan X.R et al reported that the implementation of both dietary modifications and regular physical activity resulted in a significant decrease in the occurrence rate of T2DM within a span of 6 years among individuals with prediabetes[15].

71.5% of the subjects were non-smokers (143 subjects) while 15.5% were smokers (31 subjects) and 13.0% had quit smoking (26 subjects). 53.0% of subjects had LDL dyslipidaemia (106 subjects) while 47.0% had normal LDL levels (94 subjects) The highest dyslipidaemia was observed in TG (45.0%) and the lowest in TC (35.0%).Phan DH et al estimated the prevalence of type 2 DM and prediabetes among adult from 30 to 69 years old and assess the association of risk factor with the conditions. The prediabetes prevalence was in 17.9% and diabetes in 7.3%. Patients who were male, in the 50 to 59 years old group, have hypertension and waist hip ratio (WHR) risk have higher prevalence to have prediabetes. Male patients, patients who were in 40 to 49; 50 to 59; 60 to 69 years old, those who were housewife. Diabetes has significant associated with participants have hypertension. The common factor directly related to prediabetes and diabetes in both genders is age. Other factors directly associated with prediabetes and diabetes include BMI, WHR, hypertension, educational level, and job.[16]

CONCLUSION:

Our study's findings unequivocally demonstrate that HbA1c, the established benchmark for evaluating glycemic control, exhibits a robust association with the lipid profile. The study among subjects with HbA1c levels exhibited a favorable lipid profile of TG,TC,LDL and HDL. These findings suggest a positive correlation between normoglycemic HbA1c levels and a desirable lipid profile, indicative of reduced risk. This characteristic renders it an optimal indicator for predicting dyslipidemia in individuals with type 2 diabetes mellitus.

Financial Support and Sponsorship
Nil.

Conflicts of Interest
There are no conflicts of interest.

REFERENCES:

1. Berry C, Tardif JC, Bourassa MG. Coronary heart disease in patients with diabetes: part I: recent advances in prevention and noninvasive management. J Am CollCardiol. 2007 Feb 13;49(6):631-42. doi: 10.1016/j.jacc.2006.09.046. Epub 2007 Jan 26. PMID: 17291928.
2. Ahuja M.M.S. and Vinod Kumar Progress in clinical Medicine, series one, P: 538. (1974).https://www.ijirset.com/upload/2017/may/179_CORRELATION_IEEE.pdf
3. Jamshaid T, Qureshi A. Hyperlipidemia in Diabetics. Pac Postgrad Med J 2002; 13: 159-60. DOI: 10.21474/IJAR01/4213.
4. Grundy SM. Hypertriglyceridemia, insulin resistance, and the metabolic syndrome. Am J Cardiol. 1999 May 13;83(9B):25F-29F. doi: 10.1016/s0002-9149(99)00211-8. PMID: 10357572.
5. Sreenivas Reddy A, Meera S, William E, Kumar JS. Correlation between glycemic control and lipid profile in type 2 diabetic patients: HbA1c as an indirect indicator of dyslipidemia. Asian J Pharm Clin Res 2014;7(2):153; 155. https://makhillpublications.co/files/published-files/mak-rjms/2023/9-111-115.pdf
6. Deshmukh , et al. Can HbA1c be a marker for cardiovascular risk in type 2 diabetes mellitus.Int J Med Res Rev. 2015;3:419:423. DOI: 10.17511/IJMRR.2015.I4.083
7. Trevisan R, Dodesini AR, Lepore G. Lipids and renal disease. J Am SocNephrol. 2006 Apr;17(4 Suppl 2):S145-7. doi: 10.1681/ASN.2005121320. PMID: 16565240.
8. KhareKC, Raman PG, Bhatnagar AD, ReemaBhavsar. Serum Lp(a) levels in patients of diabetes mellitus. Int. J. Diab. Dev. Countries 2000;20:79 – 83. https://www.researchgate.net/publication/267303446_Serum_Lpa_levels_in_patients_of_Diabetes_Mellitus
9. Kumar V, Madhu SV, Singh G, Gambhir JK. Post-prandial hypertriglyceridemia in patients with type 2 diabetes mellitus with and without macrovascular disease. J Assoc Physicians India. 2010 Oct;58:603-7. PMID: 21510110.
10. Pietri A, Dunn FL, Raskin P. The effect of improved diabetic control on plasma lipid and lipoprotein levels: a comparison of conventional therapy and continuous subcutaneous insulin infusion. Diabetes. 1980 Dec;29(12):1001-5. doi: 10.2337/diab.29.12.1001. PMID: 7002668.
11. Hilawe EH, Yatsuya H, Li Y, Uemura M, Wang C, Chiang C, Toyoshima H, Tamakoshi K, Zhang Y,

Kawazoe N, Aoyama A. Smoking and diabetes: is the association mediated by adiponectin, leptin, or C-reactive protein? J Epidemiol. 2015;25(2):99-109. doi: 10.2188/jea.JE20140055. Epub 2014 Nov 15. PMID: PMID: 25400076; PMCID: PMC4310870.

12. Jansen H, Stolk RP, Nolte IM, Kema IP, Wolffenbuttel BH, Snieder H. Determinants of HbA1c in nondiabetic Dutch adults: genetic loci and clinical and lifestyle parameters, and their interactions in the Lifelines Cohort Study. J Intern Med. 2013 Mar;273(3):283-93. doi: 10.1111/joim.12010. Epub 2012 Dec 5. PMID: 23121487.
13. Langer RD, Criqui MH, Reed DM. Lipoproteins and blood pressure as biological pathways for effect of moderate alcohol consumption on coronary heart disease. Circulation. 1992 Mar;85(3):910-5. doi: 10.1161/01.cir.85.3.910. PMID: 1537127.
14. Braga T, Kraemer-Aguiar LG, Docherty NG, Le Roux CW. Treating prediabetes: why and how should we do it? Minerva Med. 2019 Feb;110(1):52-61. doi: 10.23736/S0026-4806.18.05897-4. Epub 2018 Oct 29. PMID: 30371047.
15. Pan XR, Li GW, Hu YH, Wang JX, Yang WY, An ZX, Hu ZX, Lin J, Xiao JZ, Cao HB, Liu PA, Jiang XG, Jiang YY, Wang JP, Zheng H, Zhang H, Bennett PH, Howard BV. Effects of diet and exercise in preventing NIDDM in people with impaired glucose tolerance. The Da Qing IGT and Diabetes Study. Diabetes Care. 1997 Apr;20(4):537-44. doi: 10.2337/diacare.20.4.537. PMID: 9096977.
16. Phan DH, Vu TT, Doan VT, Le TQ, Nguyen TD, Van Hoang M. Assessment of the risk factors associated with type 2 diabetes and prediabetes mellitus: A national survey in Vietnam. Medicine (Baltimore). 2022 Oct 14;101(41):e31149. doi: 10.1097/MD.000000000003-1149.PMID: 36253989; PMCID: PMC9575745.

Review Article

Provisionalization in Prosthodontics: A Literature Review

Supriya Singh, Shitij Srivastava, Abhinav Shekhar, Abhishek Singh
Department of Prosthodontics and Crown & Bridge, Sardar Patel Post Graduate Institute of Dental and Medical Sciences, Lucknow (Uttar Pradesh)

ABSTRACT:

Provisionalization in prosthodontics is a crucial process in the restoration of missing teeth, where temporary prostheses are used to maintain esthetics, function, and gingival health before the final restoration is placed. The choice of materials and techniques for provisional restoration significantly influences clinical outcomes.

This review aims to provide a comprehensive analysis of the materials and techniques used in provisional restorations, with an emphasis on their functional and esthetic outcomes, as well as their impact on long-term treatment success.

A detailed literature review was conducted on studies published between 2010 and 2025, which discuss the different materials (e.g., acrylics, composite resins, and metals) and techniques (e.g., direct and indirect methods) used in provisionalization.

The review identifies that acrylic-based materials remain the most commonly used for provisional restorations due to their ease of manipulation and esthetic qualities. However, composite resins are gaining popularity for their superior mechanical properties and better fit. Additionally, the use of CAD/CAM technology for fabricating provisional restorations has been associated with improved precision and reduced chair-side time.

Provisionalization plays a significant role in the overall success of prosthodontic treatments. The choice of materials and techniques should be tailored to individual patient needs, considering factors like esthetics, functionality, and longevity. Further research is needed to evaluate the long-term effects of newer materials and digital technologies in provisional restoration fabrication.

KEY WORDS: Provisional restoration, PMMA, Bis-acryl composite, CAD/CAM, Direct technique

Address for correspondence : Dr. Supriya Singh, Post Graduate Student, Department of Prosthodontics and Crown & Bridge, Sardar Patel Post Graduate Institute of Dental and Medical Sciences, Lucknow - 226029 (Uttar Pradesh) - India.
E-mail: supriya1171@gmail.com
Submitted: 22.07.2025, **Accepted:** 25.11.2025, **Published:** 20.12.2025

INTRODUCTION:

Provisional or interim prosthesis or restoration is a fixed or removable dental or maxillofacial prosthesis designed to enhance esthetics, stabilization and/or function for a limited period of time, after which it is to be replaced by a definitive dental or maxillofacial prosthesis, according to the Glossary of Prosthodontic Term.[1]

In dentistry, temporary or interim restorations are frequently utilized during interim period between tooth preparation and definitive replacement.[2] This review collates and synthesizes existing evidence on provisionalization in prosthodontics, identifying benefits, limitations, and variations in materials and techniques. It clarifies the clinical and biological roles of provisional restorations in ensuring proper function,

Access this article online

Quick Response Code:	Website: www.pjsr.org
	DOI: https://doi.org/10.5281/zenodo.17998395

This is an open access journal, and articles are distributed under the terms of the Creative Commons Attribution-Non Commercial ShareALike 4.0 License, which allows others to remix, tweak, and build upon the work non-commercially, as long as appropriate credit is given and the new creations are licensed under the identical terms.
For reprints contact: editor.pjsr@peoplesuniversity.edu.in

How to cite this article: Singh S, Srivastava S, Shekhar A, Singh A. Provisionalization in Prosthodontics: A Literature Review. PJSR. 2025;18(2):26-34.

esthetics, and tissue protection before final prosthesis. Through systematic review of literature, it highlights gaps and inconsistencies, guiding future research and evidence-based clinical practice.[3]

CONCEPTS AND REQUIREMENTS FOR TEMPORARY CROWNS:-

These include Biomechanical, Biological and esthetic considerations.

1. BIOLOGICAL:-

- ***Pulpal protection***: Maintains pulp vitality by sealing exposed dentinal tubules and preventing microbial, thermal, and chemical insults. This is essential during endodontic therapy to prevent coronal leakage. [4]
- ***Periodontal health***: Healthy gingival tissues are maintained by smooth, plaque-resistant surfaces and proper emergence profiles. Overextended margins can cause gingival recession. [5]
- ***Tissue contour maintenance***: Proper pontic design and proximal contours preserve papillae and allow plaque control in edentulous areas.
- ***Biocompatibility***: Materials must be non-toxic and non-allergenic. Methacrylate monomers can cause allergic reactions in rare cases.[6]

2. BIOMECHANICAL:-

- ***Strength and durability***: Must withstand occlusal forces without fracture or deformation, especially in long-term cases. [7]
- ***Positional stability***: Maintains tooth position by ensuring proper proximal and occlusal contacts, preventing drifting or supraeruption.
- ***Interabutment relationship***: Preserves spatial relationship of abutments until the final prosthesis is placed.
- ***Ease of removal and recementation***: Should allow retrieval for tissue evaluation without damage or distortion.
- ***Ease of fabrication***: Should be economical, easy to manipulate, repair, and reline. Fast setting improves clinical efficiency. [8]

3. *Esthetic*:

- ***Colour and shade match***: Should harmonize with adjacent teeth for a natural appearance. [9]
- ***Surface finish***: Highly polished surfaces are necessary for esthetics and gingival health.
- ***Function and comfort***: Should restore phonetics and maintain occlusal and interproximal relationships.
- ***Diagnostic utility***: Provisionals serve as a mock-up to assess esthetics, function, and occlusion before definitive treatment. [10]

CLASSIFICATION OF PROVISIONAL RESTORATION:-

1. *ACCORDING TO THE METHOD OF FABRICATION*:

Preformed crowns:-

a) ***Resin***: Cellulose acetate, polycarbonate, photopolymerized composite resin

b) ***Metal***: Aluminum, tin–silver, nickel–chromium, and stainless steel.

Custom-made:-

a) *Direct technique:*

Base plate wax technique, shell-fabricated technique, and template-fabricated technique.

b) *Indirect technique:*

Template-fabricated provisional restoration, over impression-fabricated provisional crown, over impression-fabricated bis-acryl composite provisional, template-fabricated VLC provisional restoration, and shell-fabricated provisional restoration.

Direct and indirect combination techniques and digital techniques are the other two techniques.

2. ACCORDING TO THE PERIOD OF USE:

Long-term and short-term.

MATERIALS USED IN PROVISIONALIZATION:

Materials for provisional restorations are classified based on their chemical composition and polymerization method:

1. Chemically activated acrylic resins
2. Heat-activated acrylic resins
3. Light-activated acrylic resins
4. Dual-activated acrylic resins
5. Alloys

The most commonly used material is acrylic resin, with types including polymethyl methacrylate (PMMA), polyethyl methacrylate (PEMA), and polyvinylethyl methacrylate (PVEMA).[11,12]

POLY METHYL METHACRYLATE:

Autopolymerizing PMMA, introduced in 1940, remains widely used for provisional restorations.[13] It consists of a polymer powder (with dibutyl or diethyl phthalate) and a monomer liquid (methyl methacrylate). Available in multiple shades, PMMA offers the highest flexural strength among temporary materials.[14] However, its exothermic setting reaction can cause pulpal damage during direct fabrication, with temperatures reaching up to 82°C.

Therefore, PMMA is preferred for indirect techniques. It is more colour-stable than other methacrylates but has low abrasion resistance.[15,16,17]

***Strengthening of PMMA*:**

Crack propagation resistance is key to longevity, especially in long-span provisionals.[18] Reinforcements include fibers (glass, carbon, Kevlar) and metal structures like stainless steel meshes and wires.[18] Adequate bonding between resin and reinforcement is critical.

***Polyethyl Methacrylate (PEMA)*:**

PEMA was developed to address PMMA's drawbacks.[19] It produces less heat during setting, making it pulp-friendly for direct use. Though easy to handle and polish, it has lower strength and is less color stable, limiting its use in high-stress areas.[20,21] Splintline is a PEMA-based product.

***Polyvinylethyl Methacrylate (PVEMA)*:**

PVEMA behaves similarly to PEMA but has inferior strength and color stability compared to PMMA.[10] Its clinical use is limited. Examples include Snap, Trim, and Trim II.

***Bis-Acryl Composite Resins*:**

Bis-acryl resins offer low heat release, good marginal fit, and minimal shrinkage but are brittle and costly.[22] They are harder to repair and show reduced strength after modification.[23] Brands include Luxatemp and Protemp II.

***Bis-GMA Resins*:**

Bis-GMA materials combine the advantages of methacrylates and bis-acryls. They provide excellent marginal fit, polishability, and easier repair due to chemical compatibility with composites. [24] Tempspan and Protemp Crown are common examples.

***Visible Light-Cured (VLC) Urethane Dimethacrylate Resins*:**

Developed in the 1980s, VLC resins use light-activated polymerization with minimal monomer release, reducing toxicity.[25] They offer good strength and marginal adaptation but have poorer stain resistance and higher cost. Revotec LC is a commercially available VLC material.[26]

RECENT DEVELOPMENTS IN INTERIM FIXED RESTORATION:

Recent advancements have improved the mechanical and physical properties of temporary crown and bridge materials. Reinforcement techniques include the addition of fibers, metal oxide nanoparticles, and the adoption of CAD/CAM technology.[27]

***Fiber-Reinforced Temporary Restorations*:**

Fiber-reinforced prostheses consist of a composite substructure veneered with aesthetic materials, offering high mechanical strength and good appearance-suitable for long-term provisional restorations. Classification depends on fiber type, orientation (woven, braided, or unidirectional), and impregnation. Unidirectional glass fibers show superior flexural strength and handling properties.[28]

Common dental fibers include glass, carbon, and polyethylene. Polyethylene enhances PMMA and bis-acrylic materials with good ductility, biocompatibility, and aesthetics. Carbon fibers improve mechanical strength but are limited by poor aesthetics and possible toxicity. Fiber adhesion to resin is improved using saline coupling agents for methacrylates or bonding agents for bis-acryls. Though fiber reinforcement shows positive effects in long-span prostheses, some studies report tissue irritation and poor bonding.[29]

***Nanoparticle-Reinforced Interim Restorations*:**

Nanotechnology introduces materials like zirconium oxide, titanium oxide, and aluminum oxide to enhance temporary restorations.[30] Both surface-treated and untreated nanoparticles are used. While surface-modified nanofillers improve bonding through silane agents, they are costly. Studies also support the use of unmodified nanoparticles. [31]

Nano zirconia (ZrO_2), known for hardness and biocompatibility, improves the strength of resins with minimal aesthetic impact.[32] Combining nano-ZrO_2 with fibers further enhances flexural and impact strength. Coupling agents improve filler dispersion and adhesion to the matrix. [33]

According to Chowdhury et al. (2021), titanium and zirconium nanofillers increase PMMA's mechanical strength but may raise surface roughness, promoting microbial adhesion.

FUTURE TRENDS IN PROVISIONAL RESTORATION:-

***Digital provisional restoration*:** Digital technology has significantly advanced provisional restoration by increasing precision, efficiency, and reproducibility. A fully digital workflow involves intraoral scanning, CAD design, and CAM fabrication, minimizing manual intervention and errors.[34]

Workflow:

1. ***Intraoral scanning***: Captures accurate 3D impressions, enhancing patient comfort and reducing distortion.
2. ***CAD***: Allows detailed customization of anatomy, occlusion, and contours for improved function and esthetics.
3. ***CAM***: Produces restorations using high-performance materials like pre-polymerized PMMA or resin composites, offering excellent marginal fit and strength.

Advantages:

- Enhanced precision and fit
- Reduced chairside time with systems like CEREC
- Better material strength and esthetics
- Reproducibility of designs for future use

CAD/CAM Interim Restorations:

CAD/CAM provisional restorations, made from low-porosity blocks/discs, offer reduced polymerization shrinkage and improved mechanical properties. These are beneficial in complex cases involving TMJ disorders, vertical dimension alterations, or implant healing. Patients can digitally preview comfort and esthetics before final restorations. [35, 36]

CAD/CAM uses digital data to mill external surface form (ESF) and tissue surface form (TSF) from dense resin discs. Composite resins and CAD/CAM PMMA are common materials. Their residual monomer content is low (around 1%), reducing allergic potential. These restorations provide high wear resistance, accuracy, and biocompatibility. Diagnostic wax-ups or scans guide design, and data can be reused for final restorations. Multi-unit prostheses can also be fabricated.

Drawbacks include the need for in-office milling units, digital impression systems, and some monochromatic blanks. Milling also requires efficient coolant systems to prevent polymer clogging.[37]

3D Printing in Provisional Restorations:

Three-dimensional (3D) printing, especially Digital Light Processing (DLP), allows rapid, cost-effective production of resin prostheses. DLP uses high-power LED sources to cure entire resin layers at once, creating precise restorations with hybrid UV-curable resins.

Studies by Revilla-León et al. (2020) showed that 3D-printed interim restorations had favorable mechanical and chemical properties. Molinero-Mourelle et al. (2020) found DLP-produced methacrylate resin restorations had marginal fits within clinically acceptable limits.[38]

TECHNIQUES IN PROVISIONAL RESTORATION:

In fixed prosthodontics, fabricating temporary restorations is a critical step. Temporary restorations must fulfil essential criteria: pulpal protection, positional stability, occlusal function, cleanliness, marginal accuracy, strength, durability, and aesthetics. Once assessed intraorally, they also act as a blueprint for the definitive prosthesis.[39]

Provisional restorations play a pivotal therapeutic role in fixed prosthodontic rehabilitation, especially when they are required for extended durations or when interim treatments are needed before final restoration. Since preparation and provisionalization often occur within the same appointment, the process must be efficient. A well-executed provisional not only conserves chairside time but also enhances periodontal health and the integrity of abutments, while offering a preview of the final outcome. The literature is abundant with techniques and variations for provisional restoration fabrication. [40]

Various procedures are available, utilizing a range of materials. Despite this variability, the fundamental principle remains the same: a mold cavity is created into which a plastic material is introduced. Using a matrix, provisionals can be fabricated directly on prepared teeth, indirectly through impressions, or by combining both methods via the indirect-direct technique, where a prefabricated shell is relined intraorally.

INDIRECT PROVISIONAL FIXED PARTIAL DENTURE:-

In this technique, the temporary restoration is fabricated extraorally. The indirect method, described by Fisher et al., utilizes quick-set plaster and offers distinct advantages over direct methods.[41]

***Advantages*:**[42]

- Eliminates contact between free monomer and prepared tooth or gingiva, reducing the risk of tissue injury, hypersensitivity, or allergic reactions.
- Prevents heat from polymerizing resin from reaching the tooth.
- Saves chairside time by delegating tasks to auxiliaries.
- Yields better marginal adaptation.

***Drawbacks*:**[43]

- Requires more time and intermediate steps.
- Needs adequate lab facilities and staff.

- Diagnostic casts may cause slight inaccuracies

Method: Place acrylic tooth on diagnostic cast edentulous site and seal with carding wax. Fabricate silicone putty index extending beyond adjacent teeth. Prepare teeth, take sectional impression, pour check cast. Load index with temporary material, seat on cast, check intraoral fit, reline if needed, then finish, polish, and cement.

INDIRECT-DIRECT PROVISIONAL FIXED PARTIAL DENTURE:

This method combines extraoral fabrication of the external contours with intraoral adaptation to prepared teeth.

Advantages:

- Reduces chairside time.
- Offers better control of contours.
- Limits heat and monomer exposure.
- Reduces risk of allergic reactions. [39]

Drawbacks:

- Requires a lab phase before tooth preparation.
- May involve adjustments for shell seating.

Method: Take impression of unprepared teeth; pour diagnostic cast. Wax pontic on cast for FPD, contouring for contacts and occlusion. Lubricate cast; make elastomeric index, trim gingival edge. Prepare mock abutments conservatively on cast. Load restorative material in index; reseat on cast, polymerize, trim, and shape shell. Prepare patient's teeth; try-in, reline intraorally if needed. Polish and cement.

DIRECT PROVISIONAL FIXED PARTIAL DENTURE:

Here, the restoration is fabricated intraorally on the prepared teeth and gingiva, eliminating lab phases.

Advantages:

- Ideal when lab access is limited.

Drawbacks:

- Poorer marginal fit.
- Risk of pulpal or soft tissue injury due to exothermic polymerization.

Method: Insert acrylic tooth pre-preparation; make putty index or alginate impression. Prepare teeth. Apply petroleum jelly on teeth and gingiva. Load impression with material; reseat intraorally, removing periodically until set. Finish, polish, and cement.

OTHER DIRECT TECHNIQUES:-

I. ***Acrylic resin block technique:*** A practical, artistic method requiring no diagnostic cast.

Method: Prepare teeth. Mix acrylic to doughy stage. Seat over lubricated abutments; guide into occlusion. Remove/reseat to control heat. Carve anatomy with burs/stones after setting. Hollow internal surface, reline with fresh resin, reseat. Finish and cement with non-eugenol cement.[40]

II. ***Shell matrix method:*** Take a pre-prep impression and fabricate a shell using mouth-guard material and an acrylic tooth. Seat filled shell matrix on patient's teeth. Allow to set, finish and cement.

III. ***Alginate modification:*** Take full-arch alginate impression after wax build-up. Modify edentulous area to form a pontic or bar. Use the impression to fabricate a restoration directly.

IV. ***Using a removable partial denture (RPD)*****:** Use an RPD to imprint pontics in alginate. Use cold-cure resin to form block pontics. Attach pontics to abutment crowns or directly bond with composite.

TEMPORIZATION BEFORE TOOTH PREPARATION:

A. ***Unprepared diagnostic cast*** **:**[44]

- No modification to cast.
- Impression taken, relined intra-orally, and finished.

B. ***Prepared mock on cast*** **:**[10]

- Cast is mock-prepared.
- Shell-type provisionals fabricated and relined intraorally.

C. ***Direct Intraoral Matrix with Reline*****:**

- Follows standard direct method.

D. ***Indirect matrix on cast*****:**

- Follows standard indirect method.

TEMPORIZATION AFTER TOOTH PREPARATION:

A. ***Direct Formation on Cast:***

- Temporary restoration created post-preparation.

Options:

- Heat-cured acrylic via lost-wax.
- Self-cure acrylic, possibly fiber-reinforced.
- Light or dual-cure composites.
- Cast metal provisionals.

B. ***Prefabricated crowns:***

- Metal, polycarbonate, or cellulose acetate crowns trimmed and relined.

C. ***If patient presents without temporary:***

1. Build-up with wax, place acrylic tooth, take

C. If patient presents without temporary:

impression.

2. Use reverse pontic in impression.
3. Use acrylic block technique.

TEMPORARY POST AND CORE RESTORATIONS:

Options:

- Direct method using a ball pin.
- Indirect over-impression with embedded pin.
- Acrylic block build-up over pin.

USING EXISTING PROSTHESIS AS TEMPORARY:

When removing a permanent prosthesis:

- Section prosthesis to preserve abutments.
- Reassemble and reuse as provisional.

Advantages:

- Saves time.
- Metal reinforcement provides strength.
- Less occlusal wear.

Alternatively, take an impression before removal and fabricate the provisional from it.

MANAGEMENT OF PROVISIONAL RESTORATIONS' DEFICIENCIES:

Provisional restorations serve as critical interim prostheses in restorative and prosthodontic treatment, safeguarding the prepared tooth, maintaining occlusal function, guiding tissue healing, and fulfilling esthetic demands until the final restoration is placed. However, temporary prostheses are susceptible to various deficiencies that can compromise their function, integrity, and patient comfort.

Common Deficiencies in Provisional Restorations:-

Several issues can arise during the fabrication or intraoral use of provisional restorations:

1. Marginal discrepancies, which may lead to microleakage, gingival inflammation, and bacterial infiltration.
2. Lack of adequate retention or stability, causing premature dislodgement.
3. Poor esthetic outcome, reducing patient satisfaction, especially in the anterior region.
4. Structural fractures, often due to the use of weak or brittle materials, or mechanical stresses.

Challenges in Provisional Restorations:-

1. ***Marginal inaccuracy:***

Precise marginal fit is critical to protect the pulp from bacterial, thermal, and chemical insult. Inaccuracies can result from polymerization shrinkage (up to 6% in PMMA, 1- 4% in composite), distortion during setting, and less accurate direct fabrication methods. Repeated removal, moisture exposure, occlusal forces, and cementation may further compromise marginal integrity. Techniques such as bench polymerization, staged setting, marginal trimming, and relining improve adaptation and retention.

2. ***Fractures:***

Mechanical failure is common, particularly in long-span bridges and thin cervical regions. Material properties like flexural strength and fracture resistance are crucial; PMMA and heat-polymerized resins perform better than bis-GMA or auto/light-cured resins. Fiber reinforcement (glass, carbon, polyethylene) and metal substructures enhance strength in extensive or long-term temporization, provided placement and impregnation are correct.

3. ***External contour nonintegrity:***

Proper external morphology ensures esthetic harmony, occlusal balance, and tissue support. Poor contour can cause loss of proximal contacts, tooth drifting, improper occlusion, gingival overgrowth or collapse, and esthetic compromise. Gradual modification of the contour or emergence profile can condition soft tissues and maintain ridge form, improving esthetic and functional outcomes.

Available Materials and Bonding Strengths for Repairs, Modifications, or Relining:

Repairing or modifying provisional restorations requires compatibility between the existing base material and the newly added one. Bond strength depends on:

- Chemical similarity, with higher strength achieved when base and repair resins share similar polymer backbones.
- Surface treatment, such as roughening, monomer conditioning, or air abrasion.

Self-cure PMMA resins are widely used for repair due to their ease of manipulation and compatibility. However, these materials exhibit:

- Strong exothermic reactions
- Shrinkage during polymerization
- Residual monomer release, which may be cytotoxic or allergenic

Bis-acryl resins are preferred for their controlled mixing (via cartridge systems), low shrinkage, and better marginal accuracy. Their repair using

methacrylate resins is discouraged due to poor chemical compatibility. Instead, light-cured flowable composites offer a better repair alternative. These materials:

- Are available in a range of viscosities and shades
- Provide strong bonds with bis-acryl when combined with a bonding agent
- Show minimal polymerization shrinkage and odor

However, long-term fracture resistance in composite-to-composite repair remains questionable due to reduced bond strength over time as polymer chains become less reactive.

Particular Clinical Practices:-

Relining: Relining involves adapting the internal surface of a provisional to better fit the prepared tooth. Materials like self-cured PMMA or light-cured flowable composites are typically used. To ensure proper seating and reduce hydrostatic pressure:

- Venting should be performed
- Internal relief of the restoration is recommended
- Surface cleaning and roughening of margins enhances bonding

Firm pressure or a seating guide helps ensure full seating. Light water misting during polymerization reduces thermal impact from the exothermic reaction.

Repairs:

Repair is often more practical and economical than refabrication, but the strength of the repair is typically inferior. Common techniques include:

- Surface beveling (at 45°)
- Mechanical roughening
- Air abrasion with aluminum oxide
- Removal of contamination and aged surface layers

Use of bonding agents after these steps facilitates both chemical adhesion and mechanical interlocking.

External Modifications:

Minor additions using brush-on acrylic wash or flowable composite resins can restore contours, proximal/occlusal contacts, or improve marginal seal. These adjustments are especially helpful in:

- Modifying emergence profiles
- Managing tissue contours post-extraction
- Correcting esthetic deficits

Surface treatment is essential when bonding to older restorations, as reduced monomer content and water sorption lower bonding potential. Flowable composites, combined with bonding agents, provide a practical solution for minor intra-oral adjustments in multi-unit temporaries.

CONCLUSION:

Provisional restorations are essential in prosthodontics, protecting prepared teeth while maintaining function, esthetics, phonetics, and patient comfort. Proper material choice and fabrication techniques ensure optimal marginal fit, strength, and contour. By addressing fractures, marginal inaccuracies, and contour deficiencies, provisional restorations facilitate soft tissue conditioning and guide the final restoration. Far from being mere temporary substitutes, they serve critical diagnostic, therapeutic, and biological roles, enhancing the predictability and success of definitive prostheses and overall patient satisfaction.

Financial Support and Sponsorship

Nil.

Conflicts of Interest

There are no conflicts of interest.

REFERENCES:

1. The Glossary of Prosthodontic Terms 2023. The Journal of Prosthetic Dentistry, Volume 130, Issue 4, e1 - e3
2. Patras M, Naka O, Doukoudakis S, Pissiotis A. Management of provisional restorations' deficiencies: A literature review. J Esthet Restor Dent. 2012;24: 26–38. pmid:22296692.
3. Regish KM, Sharma D, Prithviraj DR. Techniques of fabrication of provisional restoration: an overview. Int J Dent. 2011;2011:134659. doi:10.1155/2011/134659.
4. Fox K, Gutteridge DL. An in vitro study of coronal microleakage in root-canal-treated teeth restored by the post and core technique. Int Endod J. 1997 Nov;30(6):361-8. doi: 10.1046/j.1365-2591.1997. 00093.x. PMID: 9588975.
5. Donaldson D. The Etiology of Gingival Recession Associated with Temporary Crowns. J Periodontol. 1974. Jul;45(7):468-471. doi: 10.1902/jop.1974. 45.7.468. PMID: 29538839.
6. Amet EM, Phinney TL. Fixed provisional restorations for extended prosthodontic treatment. J Oral Implantol. 1995;21(3):201-6. PMID: 8699513.
7. Doray PG, Wang X, Powers JM, Burgess JO. Accelerated aging affects color stability of provisional restorative materials. J Prosthodont. 1997 Sep;6(3) :183-8. doi: 10.1111/j.1532-849x.1997. tb00088.x.

PMID: 9497773.
8. Krug RS. Temporary resin crowns and bridges. Dent Clin North Am. 1975 Apr;19(2):313-20. PMID: 1090465.
9. Zinner ID, Trachtenberg DI, Miller RD. Provisional restorations in fixed partial prosthodontics. Dent Clin North Am. 1989 Jul;33(3):355-77. Erratum in: Dent Clin North Am. 1989 Oct;33(4):ix. PMID: 2668041.
10. Burns DR, Beck DA, Nelson SK; Committee on Research in Fixed Prosthodontics of the Academy of Fixed Prosthodontics. A review of selected dental literature on contemporary provisional fixed prosthodontic treatment: report of the Committee on Research in Fixed Prosthodontics of the Academy of Fixed Prosthodontics. J Prosthet Dent. 2003 Nov;90(5):474-97. doi: 10.1016/s0022-3913(03)00-259-2. PMID: 14586312.
11. Gratton DG, Aquilino SA. Interim restorations. Dent Clin North Am. 2004 Apr;48(2):vii, 487-97. doi: 10.1016/j.cden.2003.12.007. PMID: 15172612.
12. Boberick KG, Bachstein TK. 1998 Judson C. Hickey Scientific Writing Award. Use of a flexible cast for the indirect fabrication of provisional restorations. J Prosthet Dent. 1999 Jul;82(1):90-3. doi: 10.1016/s0022-3913(99)70132-0. PMID: 10384168.
13. Duke ES. Provisional restorative materials: a technology update. Compend Contin Educ Dent. 1999 May;20(5):497-500. PMID: 10650363.
14. Osman YI, Owen CP. Flexural strength of provisional restorative materials. J Prosthet Dent. 1993 Jul;70(1):94-6. doi: 10.1016/0022-3913(93)90038-p. PMID: 8366461.
15. Nyborg H, Brännström M. Pulp reaction to heat. J Prosthet Dent. 1968 Jun;19(6):605-12. doi: 10.1016/0022-3913(68)90262-x. PMID: 5239717.
16. Tjan AH, Grant BE, Godfrey MF 3rd. Temperature rise in the pulp chamber during fabrication of provisional crowns. J Prosthet Dent. 1989 Dec;62(6):622-6. doi: 10.1016/0022-3913(89)90578-7. PMID: 2585318.
17. Sen D, Göller G, Işsever H. The effect of two polishing pastes on the surface roughness of bis-acryl composite and methacrylate-based resins. J Prosthet Dent. 2002 Nov;88(5):527-32. doi: 10.1067/mpr.2002.129335. PMID: 12474004.
18. Amin AE. The effect of poly-aramide fiber reinforcement on the transverse strength of a provisional crown and bridge resin. Egypt Dent J. 1995 Jul;41(3):1299-304. PMID: 9497673.
19. Emtiaz S, Tarnow DP. Processed acrylic resin provisional restoration with lingual cast metal framework. J Prosthet Dent. 1998 Apr;79(4):484-8. doi: 10.1016/s0022-3913(98)70166-0. PMID: 9576327.
20. Vahidi F. The provisional restoration. Dent Clin North Am. 1987 Jul;31(3):363-81. PMID: 3301433.
21. Hernandez EP, Oshida Y, Platt JA, Andres CJ, Barco MT, Brown DT. Mechanical properties of four methyl methacrylate-based resins for provisional fixed restorations. Biomed Mater Eng. 2004;14(1):107-22. PMID: 14757958.
22. Strassler HE, Anolik C, Frey C. High-strength, aesthetic provisional restorations using a bis-acryl composite. Dent Today. 2007 Nov;26(11):128, 130-3; quiz 133, 123. PMID: 18044129.
23. Koumjian JH, Nimmo A. Evaluation of fracture resistance of resins used for provisional restorations. J Prosthet Dent. 1990 Dec;64(6):654-7. doi: 10.1016/0022-3913(90)90290-s. PMID: 2079670.
24. Castelnuovo J, Tjan AH. Temperature rise in pulpal chamber during fabrication of provisional resinous crowns. J Prosthet Dent. 1997 Nov;78(5):441-6. doi: 10.1016/s0022-3913(97)70057-x. PMID: 9399184.
25. Prestipino V. Visible Light Cured Resins: A Technique for Provisional Fixed Restorations. Quintessence Int.1989:20:241-8.
26. Haddix JE. A technique for visible light-cured provisional restorations. J Prosthet Dent. 1988 Apr;59(4):512-4. doi: 10.1016/0022-3913(88)90052-2. PMID: 3283332.
27. Alhavaz A, Rezaei Dastjerdi M, Ghasemi A, Ghasemi A, Alizadeh Sahraei A. Effect of untreated zirconium oxide nanofiller on the flexural strength and surface hardness of autopolymerized interim fixed restoration resins. J Esthet Restor Dent. 2017 Jul 8;29(4):264-269. doi: 10.1111/jerd.12300. Epub 2017 Apr 21. PMID: 28429875.
28. Alander P, Lassila LV, Vallittu PK. The span length and cross-sectional design affect values of strength. Dent Mater. 2005 Apr;21(4):347-53. doi: 10.1016/j.dental.2004.05.009. PMID: 15766581.
29. Hamouda IM, Beyari MM. Addition of glass fibers and titanium dioxide nanoparticles to the acrylic resin denture base material: comparative study with the conventional and high impact types. Oral Health Dent Manag. 2014 Mar;13(1):107-12. PMID: 24603926.
30. Sheng TJ, Shafee MF, Ariffin Z, Jaafar M. Review on poly-methyl methacrylate as denture base materials. Malaysian J Micro. 2018; 14(1):1-16.
31. Jasim BS, Ismail IJ. The effect of silanized alumina nano-fillers addition on some physical and mechanical properties of heat cured polymethyl methacrylate denture base material. J BaghColl Dent. 2014; 26(2):18–23.
32. Vojdani M, Bagheri R, Khaledi AAR. Effects of aluminum oxide addition on the flexural strength, surface hardness, and roughness of heat-polymerized acrylic resin. J Dent Sci. 2012; 7:238–244. DOI:10.1016/j.jds.2012.05.008
33. Gad MM, Fouda SM, Al-Harbi FA, Näpänkangas R, Raustia A. PMMA denture base material enhancement: a review of fiber, filler, and nanofiller addition. Int J Nanomedicine. 2017 May 17;12:3801-3812. doi: 10.2147/IJN.S130722. PMID: 28553115; PMCID: PMC5440038.
34. Güth JF, Keul C, Stimmelmayr M, Beuer F, Edelhoff D. "Digital processes for the fabrication of provisional

restorations." Journal of Prosthetic Dentistry. 2012;107(6):364-368.
35. Van der Meer WJ, Andriessen FS, Wismeijer D, Ren Y. Application of intra-oral dental scanners in the digital workflow of implantology. PLoS One. 2012;7(8):e43312. doi: 10.1371/journal.pone. 00433 12. Epub 2012 Aug 22. PMID: 22937030; PMCID: PMC3425565.
36. Vellingiri K, Nooji D, Suhas R K, Shetty B, Kumar M, Meghashr K. Current Trends in Fixed Prosthodontics. J Adv Clinic & Res Ins. 2020; 7: 51–54. DOI:10.15713/ins.jcri.304
37. Gegauff AG, Holloway JA. Interim Fixed Restorations. In: Rosenthiel SF, Land MF, Fujimoto J. Contemporary Fixed Prosthodontics. 5 th ed. St. Louis, Missouri: Elsevier Inc.; 2016: 411-449. DOI:10.33899/rdenj.2022.133218.1156
38. Molinero-Mourelle P, Gómez-Polo M, Gómez-Polo C, Ortega R, Highsmith J, Celemín-Viñuela A. Preliminary Study on the Assessment of the Marginal Fit of Three-Dimensional Methacrylate Oligomer Phosphine Oxide Provisional Fixed Dental Prostheses Made by Digital Light Processing. Prosthet. 2020; 2(3): 240– 245. https://doi.org/10.3390/prosthesis2030021
39. Dumbrigue HB. Composite indirect-direct method for fabricating multiple-unit provisional restorations. J Prosthet Dent. 2003 Jan;89(1):86-8. doi: 10.1067/mpr.2003.8. PMID: 12589294.
40. Federick DR. The provisional fixed partial denture. J Prosthet Dent. 1975 Nov;34(5):520-6. doi: 10.1016/0022-3913(75)90039-6. PMID: 1102669.
41. Boberick KG, Bachstein TK. 1998 Judson C. Hickey Scientific Writing Award. Use of a flexible cast for the indirect fabrication of provisional restorations. J Prosthet Dent. 1999 Jul;82(1):90-3. doi: 10.1016/s0022-3913(99)70132-0. PMID: 10384168.
42. Fisher DW, Shillingburg HT Jr, Dewhirst RB. Indirect temporary restorations. J Am Dent Assoc. 1971 Jan;82(1):160-3. doi: 10.14219/jada.archive.1971. 0019. PMID: 5274164.
43. Deines DN. Direct provisional restoration technique. The Journal of Prosthetic Dentistry. 1988;59(4): 395–397. doi.org/10.1016/0022-3913(88) 90029-7.
44. Dalvit DL, Parker MH, Cameron SM. Quick chairside diagnostic wax-up. J Prosthet Dent. 2002 May;87(5):581-2. doi: 10.1067/mpr.2002.124491. PMID: 12070522.

Review Article

Nutritional Deficiencies and their Impact on Oral Health

Uditi Bhadra, Sakshi Deshmukh, Swati Shrikant Gotmare
Department of Oral and Maxillofacial Pathology and Microbiology, D Y Patil University School of Dentistry, Navi Mumbai (Maharashtra)

ABSTRACT:
Nutrition plays a fundamental role in the maintenance of oral and systemic health. The oral cavity, owing to its high cellular turnover and continuous exposure to microbial, mechanical, and chemical insults, is particularly susceptible to nutritional imbalances. Deficiencies of essential macro- and micronutrients adversely affect the development, integrity, and function of teeth, gingiva, oral mucosa, salivary glands, and supporting bone. Such deficiencies may manifest as enamel hypoplasia, dental caries, periodontal disease, mucosal lesions, xerostomia, and impaired wound healing. Emerging evidence from PubMed-indexed studies highlights strong associations between nutritional inadequacies—especially deficiencies of vitamins A, B-complex, C, D, calcium, iron, and zinc—and oral diseases [1–5]. Oral manifestations often serve as early indicators of systemic nutritional deficiency, allowing dental professionals to play a crucial role in early diagnosis and prevention. This review comprehensively discusses the role of nutrition in oral health, outlines the oral manifestations of specific nutrient deficiencies, and emphasizes their clinical relevance in dental practice.

KEYWORDS: Nutrition; Nutritional deficiencies; Oral health; Periodontal disease; Dental caries

Address for correspondence : Dr. Swati Shrikant Gotmare, Department of Oral and Maxillofacial Pathology and Microbiology, D Y Patil Universsity School of Dentistry, Sector –7, Nehru Nagar, Navi Mumbai-4000706 (Maharashtra) - India.
E-mail: swatishrikant2003@gmail.com
Submitted: 19.11.2024, **Accepted:** 18.11.2025, **Published:** 22.12.2025

INTRODUCTION:

Oral health is an integral component of general health and quality of life. Oral diseases such as dental caries, periodontal disease, and oral mucosal lesions are among the most prevalent non-communicable diseases worldwide and represent a significant public health burden[15]. While dental plaque and microbial biofilms remain the primary etiological factors, increasing evidence suggests that nutritional status plays a critical role in the initiation, progression, and severity of oral diseases[2,9].

Nutrition influences tooth development, enamel mineralization, immune competence, tissue repair, and host resistance to infection[1,7]. The oral cavity, characterized by rapid epithelial turnover and constant exposure to environmental challenges, is particularly vulnerable to nutritional deficiencies. As a result, oral tissues frequently display early signs of nutritional inadequacy before systemic symptoms become apparent[14].

Changing dietary patterns, including increased consumption of refined carbohydrates and ultra-processed foods, have contributed to widespread micronutrient deficiencies, particularly among children, adolescents, elderly individuals, and socioeconomically disadvantaged populations[7,15]. Dentists are therefore uniquely positioned to detect early oral manifestations of nutritional deficiencies and initiate timely intervention. This review summarizes current evidence on nutritional deficiencies and their

Access this article online

Quick Response Code:	Website: www.pjsr.org
	DOI: https://doi.org/10.5281/zenodo.18058731

This is an open access journal, and articles are distributed under the terms of the Creative Commons Attribution-Non Commercial ShareALike 4.0 License, which allows others to remix, tweak, and build upon the work non-commercially, as long as appropriate credit is given and the new creations are licensed under the identical terms.
For reprints contact: editor.pjsr@peoplesuniversity.edu.in

How to cite this article: Bhadra U, Deshmukh S, Gotmare SK. Nutritional Deficiencies and their Impact on Oral Health. PJSR. 2025;18(2):35-41.

impact on oral health, emphasizing clinical relevance for dental practice.

Role of Nutrition in Oral Health:

Adequate nutrition is essential for the growth, development, and long-term maintenance of oral tissues. Nutrients are indispensable for the formation and mineralization of enamel and dentin, regulation of alveolar bone metabolism, preservation of periodontal ligament integrity, maintenance of salivary gland structure and function, and modulation of immune defense mechanisms within the oral cavity. Proteins, vitamins, and minerals collectively contribute to cellular turnover, collagen synthesis, antioxidant protection, and host resistance to microbial challenge. A balanced and nutrient-rich diet therefore plays a pivotal role in ensuring optimal regeneration of oral tissues, promoting effective wound healing, and enhancing resistance to both infectious and inflammatory oral diseases[1-3].

The relationship between nutrition and oral health is complex and bidirectional. Inadequate nutritional intake compromises immune function and tissue repair, predisposing individuals to a wide range of oral conditions, including dental caries, periodontal disease, oral mucosal lesions, and delayed healing following dental procedures. Conversely, the presence of oral diseases can negatively affect dietary intake by causing pain, discomfort, tooth loss, or impaired masticatory efficiency, leading to reduced food variety and compromised nutrient absorption. This vicious cycle may further aggravate existing nutritional deficiencies and contribute to disease progression. Consequently, maintaining nutritional adequacy throughout life is fundamental not only for preserving oral health but also for supporting overall systemic well-being[2,7].

Macronutrient Deficiencies and Oral Health:-

Protein Deficiency:

Proteins are fundamental to cellular growth, collagen synthesis, tissue repair, and immune defense, all of which are critical for maintaining the structural and functional integrity of oral tissues. Adequate protein intake supports continuous epithelial turnover, fibroblast activity, and synthesis of extracellular matrix components such as collagen and elastin, which are essential for gingival health and periodontal ligament stability. Protein deficiency, particularly in the form of protein–energy malnutrition, adversely affects oral tissues by impairing epithelial regeneration, reducing collagen production, and weakening both innate and adaptive immune responses.[1,9]

The oral manifestations of protein deficiency are diverse and clinically significant. These include atrophic and thin oral mucosa, increased mucosal fragility, delayed wound healing following dental extractions or periodontal therapy, heightened susceptibility to bacterial and fungal infections, and reduced salivary secretion due to salivary gland hypofunction[14]. In pediatric populations, chronic protein deficiency interferes with normal craniofacial growth and tooth development, leading to delayed tooth eruption, enamel hypoplasia, altered tooth morphology, and an increased risk of dental caries[7]. Furthermore, impaired immune competence associated with inadequate protein intake compromises the host's ability to control periodontal pathogens, thereby accelerating periodontal tissue breakdown and contributing to the progression and severity of periodontal disease[9].

Vitamin Deficiencies and Oral Manifestations:-

Vitamin A:

Vitamin A plays a pivotal role in epithelial differentiation, maintenance of mucosal integrity, and regulation of both innate and adaptive immune responses. It is essential for normal keratinocyte maturation and the preservation of a healthy, non-keratinized oral epithelium that serves as a protective barrier against microbial invasion. Deficiency of vitamin A results in abnormal keratinization and epithelial atrophy of the oral mucosa, leading to clinical manifestations such as xerostomia, mucosal dryness, and increased vulnerability to oral infections, including candidiasis[1,3].

In addition to its effects on epithelial tissues, vitamin A deficiency impairs immune function by altering lymphocyte activity and reducing antibody production. Compromise of the epithelial barrier function facilitates microbial penetration and promotes a pro-inflammatory environment within the gingival tissues. Consequently, individuals with vitamin A deficiency may exhibit increased gingival inflammation, heightened plaque-induced inflammatory responses, and a greater susceptibility to periodontal disease progression[2]. These findings highlight the importance of adequate vitamin A intake in maintaining oral mucosal health and periodontal stability.

Vitamin B-Complex:

B-complex vitamins act as coenzymes in cellular metabolism and are essential for mucosal integrity.

- **Vitamin B1 (Thiamine):** Burning mouth sensation

and neuromuscular disturbances[14].

- **Vitamin B2 (Riboflavin):** Angular cheilitis, cheilosis, and magenta tongue[14].
- **Vitamin B3 (Niacin):**Glossitis, stomatitis, and ulcerative lesions seen in pellagra[7].
- **Vitamin B6 (Pyridoxine):**Cheilosis, glossitis, and perioral dermatitis[14].
- **Vitamin B9 (Folate):** Gingivitis, mucosal ulcerations, and increased periodontal inflammation[12].
- **Vitamin B12 (Cobalamin):** Atrophic glossitis, recurrent aphthous ulcers, and burning mouth syndrome[12,14].

Recent studies demonstrate a significant association between folate and vitamin B12 deficiencies and periodontal disease severity, attributed to impaired DNA synthesis and reduced tissue turnover[12].

Vitamin C:

Vitamin C (ascorbic acid) is a critical micronutrient involved in collagen synthesis, antioxidant defense, and modulation of immune responses, all of which are essential for maintaining the structural integrity of periodontal tissues. It functions as a cofactor for prolyl and lysyl hydroxylases, enzymes necessary for the hydroxylation of collagen, thereby ensuring proper formation and stability of connective tissue fibers within the gingiva and periodontal ligament. Vitamin C also acts as a potent antioxidant, neutralizing reactive oxygen species generated during inflammatory processes and protecting oral tissues from oxidative damage.

Deficiency of vitamin C disrupts connective tissue metabolism, resulting in compromised gingival and periodontal support. Clinically, this manifests as swollen, spongy, and bleeding gums, increased gingival fragility, delayed wound healing following dental procedures, and, in severe deficiency states such as scurvy, progressive periodontal breakdown with increased tooth mobility and eventual tooth loss[5,14]. Furthermore, vitamin C deficiency impairs immune cell function, including neutrophil activity and chemotaxis, thereby reducing the host's ability to control periodontal pathogens.

Epidemiological studies have consistently demonstrated an inverse relationship between dietary vitamin C intake and periodontal disease severity, with lower intake levels associated with increased gingival inflammation, attachment loss, and periodontal pocket depth[5,18]. These findings underscore the importance of adequate vitamin C intake in preserving periodontal health and preventing the progression of inflammatory periodontal diseases.

Vitamin D:

Vitamin D plays a central role in the regulation of calcium and phosphate homeostasis and is therefore essential for normal mineralization of teeth and maintenance of alveolar bone integrity. Through its active form, 1,25-dihydroxyvitamin D, it facilitates intestinal absorption of calcium and phosphate and regulates bone remodeling by influencing osteoblast and osteoclast activity. In addition to its skeletal effects, vitamin D exerts important immunomodulatory functions by enhancing innate immunity and modulating inflammatory responses within periodontal tissues.

Deficiency of vitamin D has been associated with several adverse oral outcomes, including enamel hypoplasia, delayed tooth eruption, reduced alveolar bone density, and an increased susceptibility to periodontal disease[4,8]. Insufficient vitamin D levels may impair bone metabolism and compromise the host's ability to mount an effective immune response against periodontal pathogens, thereby contributing to periodontal tissue destruction. Recent systematic reviews and observational studies support a significant association between vitamin D deficiency and the prevalence and severity of periodontitis, particularly in adults and elderly populations[4,8]. However, evidence linking vitamin D deficiency with dental caries remains inconsistent, with studies reporting variable findings, possibly due to differences in study design, population characteristics, and confounding dietary and environmental factors. These observations highlight the importance of maintaining adequate vitamin D levels for periodontal health while underscoring the need for further research to clarify its role in caries prevention.

Vitamin K:

Vitamin K plays a crucial role in blood coagulation and bone metabolism by acting as a cofactor for the γ-carboxylation of glutamic acid residues in several clotting factors and bone-related proteins, including osteocalcin. Adequate vitamin K levels are therefore essential for maintaining hemostasis as well as supporting bone mineralization within the alveolar process. Deficiency of vitamin K compromises the synthesis of functional clotting factors, resulting in impaired coagulation.

Clinically, vitamin K deficiency may manifest

as increased gingival bleeding, spontaneous hemorrhage of the oral mucosa, and prolonged bleeding following dental extractions, periodontal procedures, or oral surgical interventions [14]. Such bleeding tendencies can complicate periodontal therapy and delay post-operative healing. Furthermore, reduced activation of osteocalcin associated with vitamin K deficiency may adversely affect alveolar bone health, potentially contributing to periodontal bone loss. These findings underscore the importance of assessing vitamin K status, particularly in patients with bleeding disorders, malabsorption syndromes, liver disease, or those receiving long-term anticoagulant therapy, to ensure safe and effective dental and periodontal management.

Mineral Deficiencies and Oral Health:

Calcium and Phosphorus:

Calcium and phosphorus are major mineral constituents of teeth and alveolar bone and play a fundamental role in the mineralization of enamel, dentin, and supporting osseous structures. These minerals exist in the form of hydroxyapatite crystals, which provide hardness and structural stability to dental hard tissues and the alveolar process. Adequate intake of calcium and phosphorus is therefore essential for maintaining tooth integrity, preserving alveolar bone mass, and ensuring the long-term stability of the periodontium.

Deficiencies in calcium and phosphorus impair mineralization processes, resulting in reduced bone density, increased tooth mobility, and a heightened susceptibility to periodontal disease[11,16]. Insufficient mineral availability compromises alveolar bone remodeling and weakens periodontal support, thereby facilitating periodontal attachment loss. Moreover, low dietary calcium intake, particularly when combined with vitamin D deficiency, has been shown to accelerate periodontal bone loss and increase the risk of tooth loss, especially among older adults[11]. These findings underscore the importance of adequate calcium and phosphorus intake, along with optimal vitamin D status, in maintaining periodontal health and preventing progressive bone destruction.

Iron:

Iron deficiency anemia is one of the most prevalent nutritional disorders worldwide and has significant implications for oral health. Iron is a critical component of hemoglobin and myoglobin, and it also plays a key role in cellular metabolism, immune function, and tissue oxygenation. Inadequate iron intake or absorption disrupts these processes, leading to systemic manifestations and notable oral signs.

Oral manifestations of iron deficiency include atrophic glossitis characterized by a smooth, erythematous, and tender tongue, angular cheilitis, pale oral mucosa, and increased susceptibility to oral infections, particularly candidiasis[14,20]. The compromised oxygen-carrying capacity and reduced immune competence in iron-deficient individuals impair tissue repair and host defense mechanisms, exacerbating oral mucosal vulnerability. Several clinical studies have reported higher periodontal indices, such as increased probing depth and attachment loss, along with greater prevalence of mucosal lesions in individuals with iron deficiency anemia[20]. These findings suggest that iron deficiency not only affects mucosal health but may also contribute to the progression of periodontal disease, highlighting the importance of early recognition and nutritional intervention in at-risk populations.

Zinc:

Zinc is an essential trace element that plays a critical role in numerous physiological processes, including immune function, cellular proliferation, wound healing, and maintenance of taste perception. Within the oral cavity, zinc contributes to the regulation of inflammatory responses, supports collagen synthesis, and enhances epithelial regeneration, all of which are vital for periodontal health[3,14].

Deficiency of zinc impairs these processes, leading to delayed oral wound healing, dysgeusia (altered taste sensation), increased susceptibility to infections, and heightened periodontal inflammation [3,14]. Mechanistically, inadequate zinc levels disrupt the activity of zinc-dependent enzymes and transcription factors that regulate oxidative stress and inflammatory cytokine production. Emerging evidence suggests that zinc deficiency may enhance oxidative stress within periodontal tissues, exacerbating tissue destruction and contributing to the progression of periodontitis[13].

Clinically, this underscores the importance of ensuring adequate zinc intake, particularly in patients with chronic periodontal disease, malabsorption

disorders, or dietary insufficiencies, to support immune competence and oral tissue repair.

Fluoride:

Fluoride is a key micronutrient that plays a critical role in the prevention of dental caries by enhancing enamel remineralization and increasing resistance to acid-induced demineralization. It incorporates into hydroxyapatite crystals of enamel to form fluorapatite, which is more resistant to dissolution by acids produced by cariogenic bacteria. In addition, fluoride exhibits antimicrobial properties by inhibiting bacterial enzymes and reducing acid production in dental biofilms[10].

Inadequate fluoride exposure, whether due to insufficient dietary intake, lack of fluoridated water, or suboptimal use of fluoride-containing dental products, is associated with an increased risk of dental caries, hypomineralization of enamel, and reduced enamel strength. Populations with low fluoride exposure often present with higher caries prevalence and more severe enamel defects, which can compromise masticatory function and increase susceptibility to further oral infections[10]. Adequate fluoride intake through community water fluoridation, dietary sources, and topical applications remains a cornerstone of preventive dentistry and a critical factor in maintaining long-term oral health.

Dietary Patterns and Oral Health:

While individual nutrients play crucial roles in maintaining oral health, overall dietary patterns have a profound and often synergistic impact on oral tissues. Diets rich in fruits, vegetables, whole grains, lean proteins, and dairy products provide a wide array of vitamins, minerals, and bioactive compounds, including antioxidants and anti-inflammatory phytochemicals, which collectively support periodontal health, enhance immune function, and promote tissue repair[6,18,19]. Adequate intake of these foods helps maintain connective tissue integrity, strengthens alveolar bone, and reduces susceptibility to periodontal inflammation.

Conversely, dietary patterns characterized by high consumption of refined sugars, processed foods, and saturated fats are strongly associated with an increased prevalence of dental caries, gingivitis, and periodontitis[7,10]. Frequent exposure to fermentable carbohydrates promotes acid production by cariogenic bacteria, leading to enamel demineralization and progression of dental caries. High-fat, low-nutrient diets may exacerbate systemic and local inflammation, further compromising periodontal tissues.

Emerging evidence suggests that adherence to Mediterranean-style dietary patterns—rich in fruits, vegetables, whole grains, nuts, fish, and olive oil—is associated with reduced periodontal inflammation, lower bleeding on probing, and improved clinical attachment levels[6,11]. These dietary approaches provide a combination of essential micronutrients, antioxidants, and anti-inflammatory compounds that act synergistically to maintain oral health. Collectively, these findings underscore the importance of evaluating diet holistically, rather than focusing solely on individual nutrients, and highlight the potential of dietary interventions as adjuncts in the prevention and management of oral diseases.

Clinical Implications for Dental Practice:

Oral manifestations frequently serve as early indicators of systemic nutritional deficiencies, often appearing before more generalized signs of malnutrition or systemic disease become evident[1,14]. Recognition of these signs by dental professionals can facilitate early diagnosis and timely intervention, potentially preventing more severe complications. For instance, conditions such as atrophic glossitis, angular cheilitis, enamel hypoplasia, and gingival bleeding may reflect deficiencies in iron, B-complex vitamins, vitamin C, or vitamin K, respectively.

Dental practitioners should therefore integrate dietary assessment and nutritional screening into routine clinical examinations. A comprehensive evaluation should include detailed dietary history, assessment of masticatory function, and consideration of systemic conditions that may affect nutrient absorption or metabolism. Interdisciplinary collaboration with physicians, dietitians, and other healthcare providers is essential to ensure a holistic approach to patient care, particularly in cases involving chronic systemic diseases, malnutrition, or complex periodontal conditions[2,9].

Incorporating nutritional counseling into dental practice can enhance patient outcomes by addressing modifiable risk factors for oral diseases. Evidence-based supplementation, tailored to

individual patient needs, may be indicated in cases of documented deficiencies or increased physiological demand. For example, supplementation with vitamin D and calcium may support alveolar bone health, while vitamin C and zinc can aid in tissue repair and immune function. Overall, integrating nutrition-focused preventive strategies and patient education into standard dental care can improve both oral and systemic health outcomes, reinforcing the pivotal role of nutrition in comprehensive dental practice[15].

CONCLUSION:

Nutritional deficiencies exert a profound influence on oral health, affecting both hard and soft tissues of the oral cavity. Deficiencies in essential vitamins and minerals compromise immune function, tissue repair, and bone metabolism, thereby increasing susceptibility to oral diseases. Early recognition of nutrition-related oral manifestations allows timely intervention and improved patient outcomes. Integrating nutritional awareness into dental education and clinical practice is essential for achieving optimal oral and systemic health.

REFERENCES:

1. Strączek A, Szałkowska J, Sutkowska P, Srebrna A, Puzio N, Piasecka A, Piskorz N, Błaszczyk J, Thum-Tyzo K. Impact of nutrition on the condition of the oral mucosa and periodontium: A narrative review. Dent Med Probl. 2023 Oct-Dec;60(4):697-707. doi: 10.17219/dmp/156466. PMID: 38133993.
2. Chapple IL, Bouchard P, Cagetti MG, Campus G, Carra MC, Cocco F, Nibali L, Hujoel P, Laine ML, Lingstrom P, Manton DJ, Montero E, Pitts N, Rangé H, Schlueter N, Teughels W, Twetman S, Van Loveren C, Van der Weijden F, Vieira AR, Schulte AG. Interaction of lifestyle, behaviour or systemic diseases with dental caries and periodontal diseases: consensus report of group 2 of the joint EFP/ORCA workshop on the boundaries between caries and periodontal diseases. J ClinPeriodontol. 2017 Mar;44 Suppl 18:S39-S51. doi: 10.1111/jcpe.12685. PMID: 28266114.
3. Zupo R, Castellana F, Sardone R, et al. Micronutrients and oral health: a systematic review. *Nutrients*. 2023;15(2):365.
4. Dietrich T, Webb I, Stenhouse L, et al. Evidence summary: the relationship between vitamin D and periodontal diseases. *Journal of Dental Research*. 2024;103(2):123–132.
5. Nishida M, Grossi SG, Dunford RG, Ho AW, Trevisan M, Genco RJ. Dietary vitamin C and the risk for periodontal disease. J Periodontol. 2000 Aug;71(8):1215-23. doi: 10.1902/jop.2000. 71.8.1215. PMID: 10972636.
6. Shi X, Zhu P, Du M, Deng K, Li P, Sáenz-Ravello G, Xu S, Li A. Dietary patterns and periodontitis: A systematic review. J Periodontal Res. 2025 Apr;60(4):300-314. doi: 10.1111/jre. 13346. Epub 2024 Sep 9. PMID: 39248151.
7. Moynihan P, Petersen PE. Diet, nutrition and the prevention of dental diseases. Public Health Nutr. 2004 Feb;7(1A):201-26. doi: 10.1079/phn2003589. PMID: 14972061.
8. Hujoel PP. Vitamin D and dental caries in controlled clinical trials: systematic review and meta-analysis. Nutr Rev. 2013 Feb;71(2):88-97. doi: 10.1111/j.1753-4887.2012.00544.x. Epub 2012 Nov 9. PMID: 23356636.
9. Genco RJ, Borgnakke WS. Risk factors for periodontal disease. Periodontol 2000. 2013 Jun;62(1):59-94. doi: 10.1111/j.1600-0757.2012.00457.x. PMID: 23574464.
10. Woelber JP, Tennert C. Chapter 13: Diet and Periodontal Diseases. Monogr Oral Sci. 2020;28:125-133. doi: 10.1159/000455380. Epub 2019 Nov 7. PMID: 31940617.
11. Krall EA, Wehler C, Garcia RI, Harris SS, Dawson-Hughes B. Calcium and vitamin D supplements reduce tooth loss in the elderly. Am J Med. 2001 Oct 15;111(6):452-6. doi: 10.1016/s0002-9343(01)00899-3. PMID: 11690570.
12. Zong G, Holtfreter B, Scott AE, Völzke H, Petersmann A, Dietrich T, Newson RS, Kocher T. Serum vitamin B12 is inversely associated with periodontal progression and risk of tooth loss: a prospective cohort study. J ClinPeriodontol. 2016 Jan;43(1):2-9. doi: 10.1111/jcpe.12483. Epub 2016 Jan 18. PMID: 26613385.
13. Kaur G, Kathariya R, Bansal S, Singh A, Shahakar D. Dietary antioxidants and their indispensable role in periodontal health. J Food Drug Anal. 2016 Apr;24(2):239-246. doi: 10.1016/j.jfda.2015.11.003. Epub 2016 Jan 8. PMID: 28911576; PMCID: PMC9339570.
14. Touger-Decker R. Oral manifestations of nutrient deficiencies. Mt Sinai J Med. 1998 Oct-Nov;65(5-6):355-61. PMID: 9844363.
15. Peres MA, Macpherson LMD, Weyant RJ, Daly B, Venturelli R, Mathur MR, Listl S, Celeste RK, Guarnizo-Herreño CC, Kearns C, Benzian H, Allison P, Watt RG. Oral diseases: a global public health challenge. Lancet. 2019 Jul 20;394(10194):249-260. doi: 10.1016/S0140-6736(19)31146-8. Erratum in: Lancet. 2019 Sep 21;394(10203):1010. doi: 10.1016/S0140-6736(19)32079-3. PMID: 31327369.

16. Al-Zahrani MS. Increased intake of dairy products is related to lower periodontitis prevalence. J Periodontol. 2006 Feb;77(2):289-94. doi: 10.1902/jop.2006.050082. PMID: 16460256.

17. Iwasaki M, Moynihan P, Manz MC, Taylor GW, Yoshihara A, Muramatsu K, Watanabe R, Miyazaki H. Dietary antioxidants and periodontal disease in community-based older Japanese: a 2-year follow-up study. Public Health Nutr. 2013 Feb;16(2):330-8. doi: 10.1017/S1368980012002637. Epub 2012 May 22. PMID: 22613693; PMCID: PMC10271354.

18. Dodington DW, Fritz PC, Sullivan PJ, Ward WE. Higher Intakes of Fruits and Vegetables, β-Carotene, Vitamin C, α-Tocopherol, EPA, and DHA Are Positively Associated with Periodontal Healing after Nonsurgical Periodontal Therapy in Nonsmokers but Not in Smokers. J Nutr. 2015 Nov;145(11):2512-9. doi: 10.3945/jn.115.211524. Epub 2015 Sep 30. PMID: 26423734.

19. Touger-Decker R, van Loveren C. Sugars and dental caries. Am J ClinNutr. 2003 Oct;78(4):881S-892S. doi: 10.1093/ajcn/78.4.881S. PMID: 14522753.

20. Velliyagounder K, Chavan K, Markowitz K. Iron Deficiency Anemia and Its Impact on Oral Health-A Literature Review. Dent J (Basel). 2024 Jun 7;12(6):176. doi: 10.3390/dj12060176. PMID: 38920877; PMCID: PMC11202564.

Case Report

ODONTOGENIC KERATOCYST A Relapse that Refuses to Rest - A Case Report

Avni Shrivastava[1], Namrata Jain[2], Priyanshi Wasalya[3], Delphina Michael Kapoor[2]
[1]Department of Oral Medicine and Radiology, [2]Department of Pediatrics and Preventive Dentistry, [3]Department of Periodontics & Implantology, Hitkarini Dental College and Hospital, Jabalpur (Madhya Pradesh)

ABSTRACT:
Odontogenic Keratocyst (OKC) is a benign cystic neoplasm that can often be misinterpreted radiographically as a dentigerous, lateral periodontal, residual, or fissural cyst. Initially, it was thought to originate from primordial odontogenic epithelium and was therefore referred to as a primordial cyst. However, the true nature of OKC—now widely recognized as a Keratocystic Odontogenic Tumor (KCOT)—remains a matter of debate.

KEY WORDS: Keratocyst, Odontogenic Cyst, Keratocystic Odontogenic Tumor.

Address for correspondence : Dr. Avni Shrivastava, BDS, Post Graduate Student, Department of Oral Medicine and Radiology Hitkarini Dental College and Hospital, Jabalpur - 482001 (Madhya Pradesh) , India, E-mail: avnishri15@gmail.com
Submitted: 10.06.2025, **Accepted:** 10.10.2025, **Published:** 22.12.2025

INTRODUCTION:

Jaw cysts, particularly Odontogenic Keratocysts (OKCs), have long intrigued dental practitioners due to their ability to grow extensively before becoming clinically apparent. Unlike other jaw cysts, OKCs exhibit a strong tendency to recur after surgical excision. Their biological nature is still unclear, which led Philipsen in 2005 to rename them as Keratocystic Odontogenic Tumors (KCOTs). Despite this, the neoplastic potential of OKC continues to be debated among oral pathologists. The present article discusses a case of OKC, with an effort to better understand its biological behaviour [1].

CASE REPORT:

A 23-year-old male patient presented with mild pain and a progressively enlarging swelling seen in the anterior one-third region of the hard palate nearing to alveolar crest the maxilla, to our department (Figure 1). There were no specific aggravating or relieving factors for past one month. Investigations revealed a previously diagnosed and treated case of OKC performed and operated a year back. Further history indicated that he had been experiencing recurrent pain in the same area following cyst removal. Intraoral and radiographic findings of the patient showed a partially edentulous maxilla involving 12, 11, 21, 22, 23 teeth, without additional symptoms (Figure 2). Orthopantomogram scans revealed bone healing (Figure 3).

CBCT radiographic scans revealed a large expansile unilocular osteolytic lesion with ill-defined and irregular bucco-lingual cortical borders (Figure 4), extending in the regions from 11 till 23, which are seen with filled obturating material. The excised specimen, measured 3 × 2 cm, was friable, thin-walled, and contained cheesy white material.

Histopathological examination revealed a cystic cavity lined with para-keratinized stratified squamous epithelium with a corrugated surface (Figure 5). The basal cells displayed palisading, with nuclei

Access this article online

Quick Response Code:	Website: www.pjsr.org
	DOI: https://doi.org/10.5281/zenodo.18045654

This is an open access journal, and articles are distributed under the terms of the Creative Commons Attribution-Non Commercial ShareALike 4.0 License, which allows others to remix, tweak, and build upon the work non-commercially, as long as appropriate credit is given and the new creations are licensed under the identical terms.
For reprints contact: editor.pjsr@peoplesuniversity.edu.in

How to cite this article: Shrivastava A, Jain N, Wasalya P, Kapoor DM. ODONTOGENIC KERATOCYST A Relapse That Refuses to Rest- A Case Report. PJSR. 2025;18(2):42-45.

Figure 1: Extra-oral appearance of the patient**.**

Figure 2:Intra-oral representation showing maxillary arch with missing teeth 12, 11, 21, 22, 23. Swelling extending 1X1 cms palatally and labially.

oriented away from the basement membrane. The epithelial-connective tissue interface was flat, occasionally showing splitting and absence of rete ridges. Capsular tissue appeared dense, with mild inflammatory infiltrates and satellite cysts noted at places. The patient was given a final diagnosis of recurrent odontogenic keratocyst. Surgical enucleation was performed successfully. A regular follow-up was done at regular intervals of 4 months for 1 year and no recurrence was reported.

DISCUSSION:

The earliest term used for OKC was *Cholesteatoma* (Hauer, 1926; Kostecka, 1929).

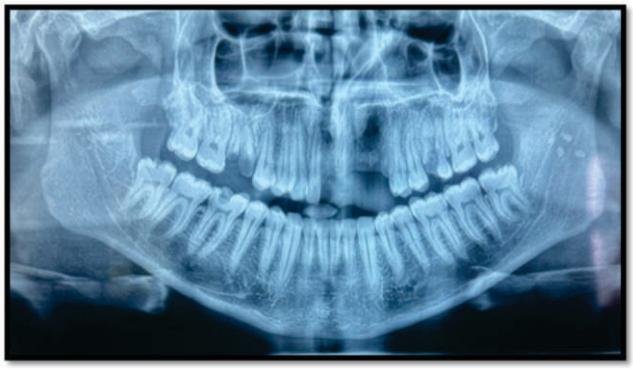

Figure 3: OPG representation of partially edentulous jaw.

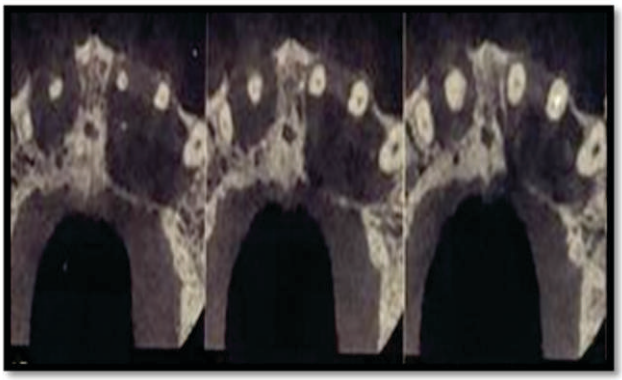

Figure 4: CBCT representation of a large osteolytic bone defect.

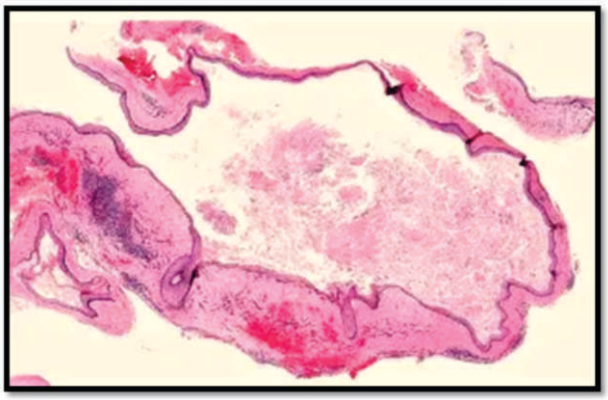

Figure 5: Histopathological findings revealing noninflamed fibrous cyst wall lined by thin uniform stratified squamous epithelium, prominent granular layer, thick luminal lamellated keratin, and cuboidal to flat basal layer.

Philipsen (1956) later introduced the term Odontogenic Keratocyst. Philipsen, Pindborg, and Hansen defined keratocysts as jaw cysts characterized by keratinization. Clinically, radiographically, and histologically, however, OKC may mimic other jaw cysts, making its classification complex[2-4].

Genetic factors are thought to play a role in its pathogenesis. OKCs are most common in the second and third decades, with a slight male predominance. The mandible, particularly the molar-ramus area, is the

most frequent site, as also observed in the present case. Symptoms may include swelling, pain, and discharge, with occasional paresthesia, although none were reported in this patient. Lesions may extend beyond 40 mm, often involving the ramus or inferior border of the mandible, while maxillary OKCs demonstrate more rapid expansion. [5]

Radiographically, OKCs may appear unilocular or multilocular, intraosseous, and often not associated with impacted teeth. Main in 1970, classified OKCs into four types: envelopmental, replacement, collateral, and extraneous. Of concern is their association with nevoid basal cell carcinoma syndrome (NBCCS), first described by Gorlin and Gotz. NBCCS is linked to mutations in the PTCH gene (chromosome 9q22.3) and presents with variable features, including multiple basal cell carcinomas, OKCs, skeletal abnormalities, and ocular manifestations[6,7].

Radiographic representation of OKC through-

OPG: They are typically seen as a solitary, radiolucent, unilocular, expansile lesion with smooth, corticated borders. These cortices are often scalloped around the roots of teeth. Three-quarters of lesions are located in the posterior mandible. When in the mandible, they typically grow along the length of the bone with minimal buccolingual expansion. In the maxilla, they expand into the maxillary sinus[8].

The appearance and location can vary. If associated with the crown of an unerupted/ impacted tooth, they can mimic a dentigerous cyst (DC). If associated with the roots of a non-vital tooth, they can mimic a radicular cyst (RC). If large enough, they will resorb the roots of adjacent teeth. They may occasionally appear septated, making the distinction from ameloblastoma difficult[9].

CT- Visualized as an expansile, cystic lesion with scalloped, well-corticated borders. Density of cystic contents varies with viscosity. Cortical breach suggests possible soft tissue involvement[9].

MRI- Odontogenic keratocysts typically demonstrate,
T1: high signal due to cholesterol and keratin contents**,**
T2: heterogeneous signal**,**
DWI/ADC: restricts due to presence of keratin**,**
T1 C+ (Gd)-peripheral enhancement, no enhancing nodular component (unlike ameloblastomas)**[10].**

The high recurrence rate of OKC is attributed to its friable epithelial lining, satellite cysts, and epithelial infoldings, making complete surgical removal challenging. Differentiating OKC from DC and orthokeratinized odontogenic cysts (OOC) is important, as OKCs exhibit more aggressive behaviour. Keratin profiling has been employed to highlight differences among these cysts[7]**.** Both DC and OKC can be positioned pericoronally; but epithelial attachment of the DC tends to attach at the cemento-enamel junction of tooth. Radicular cyst is centered at the apices of non-vital teeth and does not scallop, do not exhibit septation, and is often more expandable. Ameloblastoma-tend to be multilocular, more expansile, with a textbook soap-bubble or honeycomb appearance, tendency for ameloblastoma to be more aggressive and cause more significant tooth resorption. Long-standing OKC may mimic ameloblastoma. Ameloblastic fibroma: in younger individuals, if the lesion is pericoronal to an impacted tooth. Simple bone cyst in younger individuals can be challenging to differentiate, but usually simple bone cysts exhibit minimal expansion, and spare the lamina dura as well as the periodontal ligament spaces, odontogenic keratocysts will tend to efface the lamina dura[11].

Treatment options range from enucleation and curettage to more extensive procedures such as en-bloc resection or hemimandibulectomy, depending on lesion size. Regular postoperative follow-up is essential due to the risk of recurrence. In the present case, surgical enucleation was performed, and the patient had been under follow-up for three months without signs of recurrence[5].

CONCLUSION:

OKC or KCOT, is an aggressive lesion with a high recurrence rate. Although believed to originate from dental lamina, its exact origin remains unclear. Radiographic examination is essential for OKC diagnosis, CBCT provides high-resolution, three-dimensional images of the jaw bones and surrounding tissues, particularly useful for: assessing lesion extent and relationship with adjacent structures, evaluating cortical expansion or perforation, detecting root resorption or displacement, guiding surgical planning. While surgical excision remains the treatment of choice, adjunctive techniques such as cryotherapy, decompression, and marsupialization are also being used to minimize recurrence.

Importantly, some OKCs have shown potential for malignant transformation into squamous cell carcinoma or basal cell carcinoma. Thus, recognizing the biological behaviour and prognosis of OKC is essential for effective management.

DECLARATION OF PATIENT CONSENT:

The authors certify that they have obtained all appropriate patient consent forms. In the form, the

patient(s)/guardian has/have given his/her/their consent for his/her/their images and other clinical information to be reported in the journal. The patients/guardian understand that their names and initials will not be published and due efforts will be made to conceal their identity, but anonymity cannot be guaranteed.

Financial Support and Sponsorship
Nil.

Conflicts of Interest
There are no conflicts of interest.

REFERENCES:

1. Philipsen HP. 'Keratocysticodontogenictumor,' in World Health Organization Classification of Tumours. Pathology and Genetics of tumours of the Head and Neck. 2005: pp.306-307
2. Nayak MT, Singh A, Singhvi A, Sharma R. Odontogenickeratocyst: What is in the name? J Nat SciBiol Med. 2013 Jul;4(2):282-5. doi: 10.4103/0976-9668.116968. PMID: 24082717; PMCID: PMC3783765.
3. Philipsen HP, Reichart PA. Classification of odontogenic tumours. A historical review. J Oral Pathol Med. 2006 Oct;35(9):525-9. doi: 10.1111/j.1600-0714.2006.00470.x. PMID: 16968232.
4. Pindborg JJ, Hansen J. Studies OnOdontogenic Cyst Epithelium. 2. Clinical and Roentgenologic Aspects Of Odontogenic Keratocysts. Acta Pathol Microbiol Scand. 1963;58:283-94. PMID: 14044666.
5. Shear M, Speight P. Cysts of the Oral and Maxillofacial Regions. 4th ed, Blackwell Munksgaard, 2007.DOI:10.1002/9780470759769
6. Main DMG. Epithelial jaw cysts: a clinic-pathological reappraisal. British Journal of Oral Surgery. 1970; 8(2): 114–25. https://www.bjoms.com/article/S0007-117X(70)80002-6/fulltext
7. Gorlin RJ, Goltz RW. Multiple nevoid basal-cell epithelioma, jaw cysts and bifid rib. A syndrome. N Engl J Med. 1960 May 5;262:908-12. doi: 10.1056/NEJM 196005052621803. PMID: 13851319.
8. Scholl RJ, Kellett HM, Neumann DP, Lurie AG. Cysts and cystic lesions of the mandible: clinical and radiologic-histopathologic review. Radiographics. 1999 Sep-Oct;19(5):1107-24. doi: 10.1148/radiographics. 19.5.g99se021107. PMID: 10489168.
9. Borghesi A, Nardi C, Giannitto C, Tironi A, Maroldi R, . DiBartolomeo F, Preda L. Odontogenickeratocyst: imaging features of a benign lesion with an aggressive behaviour. Insights Imaging. 2018 Oct;9(5):883-897. doi: 10.1007/s13244-018-0644-z. Epub 2018 Jul 31. PMID: 30066143; PMCID: PMC6206371.
10. Mahmood F. Mafee, Galdino E. Valvassori, Minerva Becker. Imaging of the Head and Neck. (2005) ISBN: 9781588900098
11. Gaillard F, Ranchod A, Yap J, et al. Odontogenic-keratocyst. Reference article, Radiopaedia. org (Accessed on 17 Sep 2025) https://doi.org/10.53347/rID-1762

Case Report

Pseudocyesis or Delusion of Pregnancy- A Case Report

Garima Tomar, Akshay Upadhyay, Anshul Shakya, Vaibhav Dubey
Department of Psychiatry, People's College of Medical Sciences & Research Centre, People's University, Bhopal (Madhya Pradesh)

ABSTRACT:
Patients presenting with a firm belief of pregnancy require careful evaluation to differentiate between psychiatric and medical conditions. Pseudocyesis is a rare psychopathological condition in which a non-pregnant woman develops physical signs and symptoms mimicking pregnancy, whereas delusion of pregnancy is characterized by a fixed false belief without accompanying physical features. Accurate diagnosis is essential to avoid mismanagement and unnecessary interventions. We report a case of a 32-year-old married woman presenting with amenorrhea, breast enlargement with galactorrhea, morning sickness, and perception of fetal movements. Comprehensive gynecological evaluation and laboratory investigations revealed no evidence of pregnancy. The patient eventually accepted the absence of pregnancy, confirming the diagnosis of pseudocyesis. Psychosocial stressors, including marital discord and fear of divorce, appeared to exacerbate her psychological state. This case highlights the importance of detailed history taking, clinical examination, and multidisciplinary evaluation in distinguishing pseudocyesis from delusion of pregnancy.

KEY WORDS: Pseudocyesis, Delusion of pregnancy, Psychosomatic disorder, Marital stress, Diagnosis

Address for correspondence : Dr. Garima Tomar, MBBS, Post Graduate Student, Department of Psychiatry, People's College of Medical Sciences & Research Centre, People's University, Bhopal, Madhya Pradesh, India - 462037 (Madhya Pradesh), India, E-mail: drgarimatomar911@gmail.com
Submitted: 14.08.2025, **Accepted:** 10.11.2025, **Published:** 22.12.2025

INTRODUCTION:

Pseudocyesis is a rare psychiatric condition in which a woman who is not pregnant firmly believes herself to be pregnant and exhibits multiple physical and subjective features suggestive of pregnancy.[1] In contrast, delusion of pregnancy refers to an unshakeable belief of being pregnant in the absence of physical signs and despite objective medical evidence disproving pregnancy.[2] Accurate differentiation between these two conditions is crucial, as misdiagnosis may result in inappropriate treatment and prolonged psychological distress. The present case was identified in the psychiatric outpatient department based on clinical features consistent with pseudocyesis.

CASE REPORT:

A 32-year-old married woman, a housewife and mother of two children, presented to the psychiatric outpatient department with concerns regarding a possible pregnancy. She belonged to a low socioeconomic background and was a devout Muslim. There was a significant family history of psychiatric illness, with psychosis reported in her mother and bipolar affective disorder in her elder sister. The patient had a past history of Acute Transient Psychotic Disorder (ATPD), which had resolved completely

Access this article online

Quick Response Code:	Website: www.pjsr.org
	DOI: https://doi.org/10.5281/zenodo.18046085

This is an open access journal, and articles are distributed under the terms of the Creative Commons Attribution-Non Commercial ShareALike 4.0 License, which allows others to remix, tweak, and build upon the work non-commercially, as long as appropriate credit is given and the new creations are licensed under the identical terms.
For reprints contact: editor.pjsr@peoplesuniversity.edu.in

How to cite this article: Tomar G, Upadhyay A, Shakya A, Dubey V. Pseudocyesis or Delusion of Pregnancy- A Case Report. PJSR. 2025;18(2):46-48.

within 15 days following pharmacological treatment. The patient reported cessation of menstruation for the past five months, along with symptoms commonly associated with pregnancy, including morning sickness, breast enlargement with milky discharge, and perception of fetal movements. Despite these symptoms, a home urine pregnancy test was negative. At the time of presentation, she was residing with her parents following separation from her husband, who was planning to remarry and had expressed his intention to seek a divorce. These interpersonal conflicts were associated with significant psychological stress.

A comprehensive medical evaluation was undertaken, including gynecological consultation and relevant investigations. Clinical examination revealed no evidence of pregnancy. Abdominal ultrasonography showed no gestational sac. Laboratory investigations, including serum beta-human chorionic gonadotropin (β-hCG), serum prolactin levels, and thyroid function tests, were within normal limits. Following detailed explanation of the findings and supportive counseling, the patient accepted that she was not pregnant. Based on the presence of pregnancy-like physical symptoms in the absence of actual pregnancy and subsequent acceptance of reality, a diagnosis of pseudocyesis was made.

DISCUSSION:

Pseudocyesis represents a complex interplay of psychological vulnerability, social stressors, and biological influences. Factors such as marital discord, fear of abandonment, and sociocultural expectations related to fertility have been frequently associated with its onset. In contrast to delusion of pregnancy, pseudocyesis is characterized by the presence of physical manifestations resembling pregnancy.

In the present case, significant interpersonal stress arising from marital separation and the possibility of divorce appeared to act as precipitating factors, contributing to the intensity of symptoms.[3] Psychological mechanisms underlying pseudocyesis often include an intense desire for or fear of pregnancy, accompanied by emotional distress.[4] A prior psychiatric illness and positive family history may have further increased the patient's susceptibility.

The condition differs from delusion of pregnancy in that symptoms resembling pregnancy are present despite the absence of a fetus, and the patient ultimately acknowledges the absence of pregnancy. In delusion of pregnancy, the belief remains purely psychological and persists even in the absence of physical symptoms and in the face of clear contradictory evidence.[5] Early diagnosis and empathetic communication facilitated acceptance in this case, preventing unnecessary medical interventions.

CONCLUSION:

This case highlights that pregnancy-like symptoms do not invariably indicate true pregnancy or a delusional disorder. Thorough history taking, detailed clinical assessment, and appropriate investigations are essential to distinguish pseudocyesis from delusion of pregnancy. Addressing psychosocial stressors and providing timely psychiatric intervention can lead to favorable clinical outcomes.

DECLARATION OF PATIENT CONSENT:

The authors certify that they have obtained all appropriate patient consent forms. In the form, the patient(s)/guardian has/have given his/her/their consent for his/her/their images and other clinical information to be reported in the journal. The patients/guardian understand that their names and initials will not be published and due efforts will be made to conceal their identity, but anonymity cannot be guaranteed.

Financial Support and Sponsorship
Nil.

Conflicts of Interest
There are no conflicts of interest.

REFERENCES:

1. Azizi M, Elyasi F. Biopsychosocial view to pseudocyesis: A narrative review. Int J Reprod Biomed. 2017 Sep;15(9):535-542. PMID: 29662961; PMCID: PMC5894469.
2. Das S, Prasad S, Ajay Kumar S, Denise Makonyonga R, Saadoun M, Mergler R. Delusion of Pregnancy: A Case Report and Literature Review. Clin Med Insights Case Rep. 2023 Apr 2;16:11795476231161169. doi: 10.1177/11795476231161169. PMID: 37033675; PMCID: PMC10074635.
3. Kassim FM, Wasihun MT, Jimma MA, Megersa SW. The role of sociocultural factors in rare medical conditions: The first case report of pseudocyesis in an Ethiopian woman with major depressive disorder. Clin Case Rep. 2024 May 7;12(5):e8888. doi: 10.1002/

ccr3.8888. PMID: 38721559; PMCID: PMC11077235.

4. Nguyen E, Watkins A, Wells L. Pseudocyesis in a deployed military member. *Psychiatry Res Case Rep*. 2023.DOI:10.1016/j.psycr.2023.100183. Corpus ID: 263807166
5. Seeman MV. Pseudocyesis, delusional pregnancy, and psychosis: The birth of a delusion. World J Clin Cases. 2014 Aug 16;2(8):338-44. doi: 10.12998/wjcc.v2.i8.328. PMID: 25133144; PMCID: PMC4133423.

Case Report

Escitalopram-induced Bullous Pemphigoid: A Case Report

Akshay Upadhyay, Anshul Shakya, Garima Tomar, Vaibhav Dubey
Department of Psychiatry, People's College of Medical Sciences & Research Centre, People's University, Bhopal (Madhya Pradesh)

ABSTRACT:
Bullous pemphigoid is an autoimmune blistering disorder affecting elderly individuals. Emerging evidence links selective serotonin reuptake inhibitors (SSRIs) to bullous pemphigoid development. A 64-year-old man with hypertension, Type-2 diabetes mellitus, hypothyroidism, developed widespread blisters one week after starting escitalopram 10 mg daily. Histopathology and serology confirmed bullous pemphigoid. Naranjo Adverse Drug Reaction Probability Scale score was 4 (possible adverse reaction), with positive findings for temporal relationship. After stopping escitalopram and initiating melatonin, corticosteroids, doxycycline, & antihistaminergic complete resolution occurred within 6 weeks. Clinicians should remain vigilant for drug-induced bullous pemphigoid in elderly patients on SSRIs presenting with new-onset blistering. Early recognition and drug discontinuation lead to favourable outcomes.

KEY WORDS: Bullous pemphigoid, escitalopram, drug-induced autoimmune disease, Naranjo scale, polypharmacy

Address for correspondence : Dr. AkshayUpadhyay, MBBS, Post Graduate Student, Department of Psychiatry, People's College of Medical Sciences & Research Centre, People's University, Bhopal, Madhya Pradesh, India - 462037 (Madhya Pradesh), India, E-mail: dr.akshay@yahoo.com
Submitted: 08.08.2025, **Accepted:** 16.11.2025, **Published:** 23.12.2025

INTRODUCTION:

Bullous pemphigoid is the most common autoimmune subepidermal blistering disease, predominantly affecting individuals over 60 years.[1] The condition results from autoantibodies against hemidesmosomal proteins BP180 and BP230, causing basement membrane disruption and blister formation.[2] Recent large-scale studies demonstrate strong associations between neuropsychiatric medications, particularly selective serotonin reuptake inhibitors (SSRIs), and bullous pemphigoid development.[3,4] The pathophysiology remains incompletely understood but likely involves antigen modification, immune dysregulation, and cross-reactive responses between neural and cutaneous antigens.[5,6]

Managing drug-induced bullous pemphigoid in elderly patients with polypharmacy presents unique challenges, as polypharmacy independently increases mortality risk in bullous pemphigoid.[7] We present a case of escitalopram-induced bullous pemphigoid highlighting diagnostic and management considerations.

CASE REPORT:

A 64-year-old male, presented with pruritic, blistering eruption for 1 week starting from dorsal aspect of right hand and gradually spreading over torso, legs, scalp, neck & groin (Figure 1). Patient was referred to psychiatry department for disturbance in sleep from dermatology department, on further

Access this article online

Quick Response Code:	Website: www.pjsr.org
	DOI: https://doi.org/10.5281/zenodo.18058250

This is an open access journal, and articles are distributed under the terms of the Creative Commons Attribution-Non Commercial ShareALike 4.0 License, which allows others to remix, tweak, and build upon the work non-commercially, as long as appropriate credit is given and the new creations are licensed under the identical terms.
For reprints contact: editor.pjsr@peoplesuniversity.edu.in

How to cite this article: Upadhyay A, Shakya A, Tomar G, Dubey V. Escitalopram-induced Bullous Pemphigoid: A Case Report. PJSR. 2025;18(2):49-52.

Figure 1: Shows the trunk of the patient with multiple intact vesicles and bullae, and ruptured bullae with erosions and crusting.

evaluation we found that patient had been started on Escitalopram 10mg & clonazepam 0.5mg 10 days prior of developing cutaneous symptoms by a neurologist for sleep disturbance. His past medical history included hypertension, Type-2 diabetes mellitus, hypothyroidism with history of CVA 1 year ago & disturbance in sleep. His treatment comprised of Tablet telmisartan 40mg, metoprolol 20mg, thyroxine75 mcg, metformin 500mg, aspirin 75mg and atorvastatin 20mg. On examination patient presented with widespread erosions affecting the whole body with tense blisters, serology and biopsy suggestive of bullous pemphigoid. Hamilton depression rating scale score was *6* at day 3rd of admission. On Naranjo Adverse Drug Reaction Probability Scale the score was 4 (Possible adverse drug reaction).

Escitalopram was discontinued as it was identified as a potential trigger, and was prescribed melatonin 5 mg at bedtime and zolpidem 5 mg as needed for sleep management. The endocrinologist-initiated insulin therapy, while the dermatologists managed the patient with dexamethasone, doxycycline, antihistaminergic & topical ointments. After stopping the potential trigger medication, there was a gradual reduction in the formation of new blisters and improvement in sleep. The patient was discharged from hospital after an intensive 6 weeks of treatment. The follw-up was done till 1 year and no recurrence was seen.

DISCUSSION:

This case demonstrates escitalopram-induced Bullous Pemphigoid in an elderly patient with multiple co-morbidities. The Naranjo score of 4 supports probable causality, with clear temporal relationship and resolution after drug discontinuation.

Varpuluoma et al. found significant associations between SSRIs (particularly escitalopram) and bullous pemphigoid in a Finnish registry study.[3] While mechanisms remain unclear, proposed pathways include antigen modification exposing cryptic epitopes, neoantigen formation, and immune dysregulation.[5,8,9]

Bullous pemphigoid patients show higher prevalence of psychiatric disorders (OR 1.77), with anxiety and depression potentially predisposing to bullous pemphigoid development.[10,11] Shared mechanisms include neuroinflammation and cross-reactive immune responses to BP180/BP230, expressed in both neural and cutaneous tissues.[12] Our patient's minimal depression score: 6 suggests even mild psychiatric indications for SSRIs may carry bullous pemphigoid risk in vulnerable populations.

Polypharmacy correlates with increased bullous pemphigoid mortality.[13,14] Systematic medication review is essential when elderly patients develop new symptoms. Managing multiple conditions requires balancing therapeutic needs against adverse reaction risks.

Melatonin effectively regulates circadian rhythms with excellent safety profiles in elderly populations.[15] Combined with PRN zolpidem, this approach addressed insomnia while avoiding SSRI-associated bullous pemphigoid risk.[16,17]

In elderly patients with co-morbidities, systemic corticosteroids carry significant risks including hyperglycemia, hypertension, and infections.[18] Drug-induced BP prognosis is generally favorable with prompt drug withdrawal, though close monitoring remains essential.[19]

CONCLUSION:

This case of escitalopram-induced bullous pemphigoid demonstrates the importance of recognizing SSRIs as potential triggers in elderly patients. The Naranjo score of 4 supports probable

improvement after discontinuation, and objective confirmation.

Maintaining vigilance for cutaneous adverse effects when prescribing SSRIs to elderly patients, considering drug-induced bullous pemphigoid in patients on psychotropic medications with new-onset blistering, conducting systematic medication reviews in polypharmacy contexts, and recognizing that alternative psychiatric treatments can effectively manage symptoms after serious drug reactions.

Early recognition and prompt drug withdrawal with appropriate multidisciplinary management achieved complete resolution. However, the increased morbidity and mortality in elderly BP populations emphasize prevention through judicious prescribing.

Further research is needed to elucidate escitalopram-bullous pemphigoid mechanisms, identify susceptibility markers, and develop evidence-based guidelines for managing psychiatric symptoms in at-risk patients. Enhanced clinical awareness will facilitate earlier diagnosis and improved outcomes.

DECLARATION OF PATIENT CONSENT:

The authors certify that they have obtained all appropriate patient consent forms. In the form, the patient(s)/guardian has/have given his/her/their consent for his/her/their images and other clinical information to be reported in the journal. The patients/guardian understand that their names and initials will not be published and due efforts will be made to conceal their identity, but anonymity cannot be guaranteed.

Financial Support and Sponsorship
Nil.

Conflicts of Interest

There are no conflicts of interest.

REFERENCES:

1. Schmidt E, Zillikens D. Pemphigoid diseases. Lancet. 2013 Jan 26;381(9863):320-32. doi: 10.1016/S0140-6736(12)61140-4. Epub 2012 Dec 11. PMID: 23237497.
2. Kasperkiewicz M, Zillikens D. The pathophysiology of bullous pemphigoid. Clin Rev Allergy Immunol. 2007 Oct;33(1-2):67-77. doi: 10.1007/s12016-007-0030-y. PMID: 18094948.
3. Varpuluoma O, Jokelainen J, Försti AK, Turpeinen M, Timonen M, Huilaja L, Tasanen K. Drugs used for neurologic and psychiatric conditions increase the risk for bullous pemphigoid: A case-control study. J Am AcadDermatol. 2019 Jul;81(1):250-253. doi: 10.1016/j.jaad.2019.02.017. Epub 2019 Feb 13. PMID: 30771421.
4. Bastuji-Garin S, Joly P, Lemordant P, Sparsa A, Bedane C, Delaporte E, Roujeau JC, Bernard P, Guillaume JC, Ingen-Housz-Oro S, Maillard H, Pauwels C, Picard-Dahan C, Dutronc Y, Richard MA; French Study Group for Bullous Diseases. Risk factors for bullous pemphigoid in the elderly: a prospective case-control study. J Invest Dermatol. 2011 Mar;131(3):637-43. doi: 10.1038/jid.2010.301. Epub 2010 Oct 14. PMID: 20944650.
5. Stavropoulos PG, Soura E, Antoniou C. Drug-induced pemphigoid: a review of the literature. J EurAcadDermatolVenereol. 2014 Sep;28(9):1133-40. doi: 10.1111/jdv.12366. Epub 2014 Jan 10. PMID: 24404939.
6. Verheyden MJ, Bilgic A, Murrell DF. A Systematic Review of Drug-Induced Pemphigoid. ActaDermVenereol. 2020 Aug 17;100(15):adv00224. doi: 10.2340/00015555-3457. PMID: 32176310; PMCID: PMC9207627.
7. Kalinska-Bienias A, Lukowska-Smorawska K, Jagielski P, Kowalewski C, Wozniak K. Mortality in bullous pemphigoid and prognostic factors in 1st and 3rd year of follow-up in specialized centre in Poland. Arch Dermatol Res. 2017 Nov;309(9):709-719. doi: 10.1007/s00403-017-1772-x. Epub 2017 Aug 29. PMID: 28852833.
8. Naranjo CA, Busto U, Sellers EM, Sandor P, Ruiz I, Roberts EA, Janecek E, Domecq C, Greenblatt DJ. A method for estimating the probability of adverse drug reactions. ClinPharmacolTher. 1981 Aug;30(2):239-45. doi: 10.1038/clpt.1981.154. PMID: 7249508.
9. de Nicolas-Ruanes B, Ballester-Martinez A, Garcia-Mouronte E, Berna-Rico E, Azcarraga-Llobet C, Fernandez-Guarino M. From Molecular Insights to Clinical Perspectives in Drug-Associated Bullous Pemphigoid. Int J Mol Sci. 2023 Nov 26;24(23):16786. doi: 10.3390/ijms242316786. PMID: 38069109; PMCID: PMC10706090.
10. Huang F, Cai T, Wang D, et al. Association between bullous pemphigoid and psychiatric disorders. *J Dtsch Dermatol Ges*. 2022;20(9):1195-1203.DOI: 10.1111/ddg.14852
11. Kridin K, Hundt JE, Ludwig RJ, et al. Anxiety and depression predispose to bullous pemphigoid. *Curr Psychol*. 2023;42:4799-4805. 10.1007/s12144-021-01396-1
12. Rania M, Petersen LV, Benros ME, Liu Z, Diaz L, Bulik CM. Psychiatric comorbidity in individuals with bullous pemphigoid and all bullous disorders in the Danish national registers. BMC Psychiatry. 2020 Aug 20;20(1):411. doi: 10.1186/s12888-020-02810-x. Erratum in: BMC Psychiatry. 2020 Sep 4;20(1):432. doi: 10.1186/s12888-020-02842-3. PMID: 32819315; PMCID: PMC7439544.

13. Joly P, Baricault S, Sparsa A, Bernard P, Bédane C, Duvert-Lehembre S, Courville P, Bravard P, Rémond B, Doffoel-Hantz V, Bénichou J. Incidence and mortality of bullous pemphigoid in France. J Invest Dermatol. 2012 Aug;132(8):1998-2004. doi: 10.1038/jid.2012.35. Epub 2012 Mar 15. PMID: 22418872.
14. Langan SM, Smeeth L, Hubbard R, Fleming KM, Smith CJ, West J. Bullous pemphigoid and pemphigus vulgaris--incidence and mortality in the UK: population based cohort study. BMJ. 2008 Jul 9;337(7662):a180. doi: 10.1136/bmj.a180. PMID: 18614511; PMCID: PMC2483869.
15. Langan SM, Smeeth L, Hubbard R, Fleming KM, Smith CJ, West J. Bullous pemphigoid and pemphigus vulgaris--incidence and mortality in the UK: population based cohort study. BMJ. 2008 Jul 9;337(7662):a180. doi: 10.1136/bmj.a180. PMID: 18614511; PMCID: PMC2483869.
16. Stoianovici R, Brunetti L, Adams CD. Comparison of Melatonin and Zolpidem for Sleep in an Academic Community Hospital: An Analysis of Patient Perception and Inpatient Outcomes. J Pharm Pract. 2021 Feb;34(1):44-50. doi: 10.1177/0897190019851888. Epub 2019 Jun 25. PMID: 31238791.
17. Dang A, Garg A, Rataboli PV. Role of zolpidem in the management of insomnia. CNS NeurosciTher. 2011 Oct;17(5):387-97. doi: 10.1111/j.1755-5949.2010.00158.x. Epub 2010 Jun 11. PMID: 20553305; PMCID: PMC6493830.
18. Kenna HA, Poon AW, de los Angeles CP, Koran LM. Psychiatric complications of treatment with corticosteroids: review with case report. Psychiatry ClinNeurosci. 2011 Oct;65(6):549-60. doi: 10.1111/j.1440-1819.2011.02260.x. PMID: 22003987.
19. Werth VP, Murrell DF, Joly P, Ardeleanu M, Hultsch V. Bullous pemphigoid burden of disease, management and unmet therapeutic needs. J Eur Acad Dermatol Venereol. 2025 Feb;39(2):290-300. doi: 10.1111/jdv.20313. Epub 2024 Sep 19. PMID: 39297242; PMCID: PMC11760689.

Case Report

Diagnostic & Management Dilemma in Atropine induced Psychosis with Restless Leg Syndrome – A Case Report

Anshul Shakya, Garima Tomar, Akshay Upadhyay, Vaibhav Dubey
Department of Psychiatry, People's College of Medical Sciences & Research Centre, People's University, Bhopal (Madhya Pradesh)

ABSTRACT:
Anticholinergic medications are commonly used yet frequently overlooked as potential causes of isolated neuropsychiatric symptoms. While acute atropine toxicity produces a characteristic peripheral and central anticholinergic toxidrome, chronic low-dose exposure may manifest exclusively with psychotic symptoms. We present a case of a 48-year-old male who developed persistent auditory hallucinations and delusional beliefs following prolonged use of diphenoxylate–atropine. Symptoms resolved rapidly after discontinuation of the medication and initiation of pregabalin for co-existing Restless Leg Syndrome (RLS). This case highlights the importance of considering anticholinergic-induced psychosis in patients presenting with new-onset hallucinations and emphasizes the need for careful review of chronic anticholinergic use before initiating antipsychotic therapy.

KEY WORDS: Anticholinergic Psychosis, Atropine, Restless Leg Syndrome, Substance-Induced Psychosis, Diphenoxylate–Atropine

Address for correspondence : Dr. Anshul Shakya, MBBS, Post Graduate Student, Department of Psychiatry, People's College of Medical Sciences & Research Centre, People's University, Bhopal, Madhya Pradesh, India - 462037 (Madhya Pradesh), India, E-mail: gmc.anshul@gmail.com
Submitted: 22.07.2025, **Accepted:** 29.11.2025, **Published:** 23.12.2025

INTRODUCTION:

Anticholinergic toxicity classically presents with a constellation of cognitive, autonomic, and neuromuscular features summarized by the mnemonic "mad as a hatter, blind as a bat, red as a beet, dry as a bone, hot as a hare".[1] While these symptoms are well documented in acute overdose, prolonged low-dose exposure may result primarily in central effects such as hallucinations, agitation, delusions, and confusion, often without typical peripheral signs.[2-4]

Atropine-induced psychosis remains under-recognized and may mimic primary psychiatric disorders, delaying accurate diagnosis and leading to unnecessary antipsychotic treatment. Additionally, misuse of anticholinergic-containing medications has been increasingly reported in individuals with substance dependence or chronic uncomfortable sensory states such as Restless Leg Syndrome (RLS).[5] This case highlights a rare presentation of chronic atropine-associated psychosis with co-existing RLS.

CASE REPORT:

A 48-year-old male presented with a six-month history of auditory hallucinations, predominantly hearing a female voice at night, which he misattributed to his wife. This progressed to a fixed delusion of infidelity, causing interpersonal distress. There were no features of delirium, confusion, or fluctuating sensorium.

Access this article online

Quick Response Code:	Website: www.pjsr.org
	DOI: https://doi.org/10.5281/zenodo.18058286

This is an open access journal, and articles are distributed under the terms of the Creative Commons Attribution-Non Commercial ShareALike 4.0 License, which allows others to remix, tweak, and build upon the work non-commercially, as long as appropriate credit is given and the new creations are licensed under the identical terms.
For reprints contact: editor.pjsr@peoplesuniversity.edu.in

How to cite this article: Shakya A, Tomar G, Upadhyay A, Dubey V. Diagnostic & Management Dilemma in Atropine induced Psychosis with Restless Leg Syndrome – A Case Report . PJSR. 2025;18(2):53-55.

Past History and Medication Use:

He had a previous history of opioid use disorder (2014–2018), currently abstinent. Since 2019, he had been self-administering diphenoxylate–atropine (Lomotil), starting at ~10 tablets/day and tapering to 4 tablets/day over the past several years. He reported taking it for relief of uncomfortable sensations in the legs consistent with Restless Leg Syndrome, which worsened when the medication was withheld.

Mental Status Examination:

- Auditory hallucinations (third-person running commentary)
- Delusion of infidelity
- No visual hallucinations
- No autonomic features of anticholinergic syndrome
- No cognitive impairment or disorientation

DIAGNOSIS:

Based on symptom chronology and medication history, he was diagnosed with Substance/ Medication-Induced Psychotic Disorder, likely attributable to chronic anticholinergic exposure.

MANAGEMENT:

Diphenoxylate–atropine was discontinued immediately. He was started on pregabalin 75 mg at bedtime for RLS.

OUTCOME:

Within seven days, there was:

- Complete resolution of hallucinations
- Significant reduction in delusional beliefs
- Marked improvement in RLS symptoms without recurrence

He remained stable on follow-up, without requiring antipsychotic medication.

DISCUSSION

Anticholinergic psychosis is mediated primarily through central muscarinic receptor blockade, disrupting cholinergic–dopaminergic balance in the cortex and limbic structures.[6,7] While acute atropine intoxication is well described, there is growing recognition that chronic exposure to low doses of anticholinergic agents-including atropine, trihexyphenidyl, and diphenoxylate—may produce primarily psychiatric symptoms such as hallucinations, agitation, affective instability, or delusions.[8–10]

In this case, the patient presented with pure psychotic symptoms without typical anticholinergic signs such as mydriasis, tachycardia, hyperthermia, urinary retention, or dry mucous membranes. Similar cases of isolated atropine-induced psychosis have been documented in the literature.[11–12]

Relationship with Restless Leg Syndrome (RLS):

Although diphenoxylate–atropine is not an established therapy for RLS, patients may self-medicate due to sedative or anxiolytic effects. RLS is associated with dopaminergic dysfunction, and anticholinergic medications may transiently modulate sensory symptoms, explaining the patient's perceived benefit.[13]

Effective treatment of RLS with pregabalin is consistent with evidence showing benefit of alpha-2-delta ligands in sensorimotor symptoms.[14]

Clinical Importance:

This case demonstrates several key points:

1. Chronic anticholinergic use can cause isolated psychosis in the absence of classic toxidrome.
2. Stopping the offending agent is often sufficient, preventing unnecessary exposure to antipsychotics.
3. Anticholinergic medications frequently used in psychiatry (e.g., trihexyphenidyl) may worsen psychosis and should be monitored closely.[15]
4. Detailed medication history remains essential in evaluating first-episode psychosis.

CONCLUSION:

Chronic use of anticholinergic medications such as diphenoxylate–atropine can lead to isolated psychosis without peripheral toxicity. Clinicians must maintain a high index of suspicion for medication-induced psychosis, particularly in individuals with prolonged exposure. Prompt discontinuation and targeted treatment of underlying symptoms such as RLS can result in rapid and complete recovery.

DECLARATION OF PATIENT CONSENT:

The authors certify that they have obtained all appropriate patient consent forms. In the form, the patient(s)/guardian has/have given his/her/their consent for his/her/their images and other clinical information to be reported in the journal. The patients/guardian understand that their names and initials will not be published and due efforts will be made to conceal their identity, but anonymity cannot be guaranteed.

Financial Support and Sponsorship
Nil.

Conflicts of Interest
There are no conflicts of interest.

REFERENCES:

1. Broderick ED, Metheny H, Crosby B. Anticholinergic Toxicity. [Updated 2023 Apr 30]. In: StatPearls [Internet]. Treasure Island (FL): StatPearls Publishing; 2025 Jan.
2. Tune LE. Anticholinergic effects of medication in elderly patients. J Clin Psychiatry. 2001;62 Suppl 21:11-4. PMID: 11584981.
3. Panchasara A, Mandavia D, Anovadiya AP, Tripathi CB. Central anti-cholinergic syndrome induced by single therapeutic dose of atropine. Curr Drug Saf. 2012 Feb;7(1):35-6. doi: 10.2174/-157488612800492799. PMID: 22663956.
4. Talabaki H, Soltani M, Abbasi A, Sharifi V, Salehi N, Zakariaei Z. Neuropsychiatric manifestations due to anticholinergic agents and anabolic steroids ingestion: A case series and literature review. Neuropsychopharmacol Rep. 2024 Sep;44(3):540-544. doi: 10.1002/npr2.12460. Epub 2024 Jun 18. PMID: 38889254; PMCID: PMC11544456.
5. Chiappini S, Mosca A, Miuli A, Semeraro FM, Mancusi G, Santovito MC, Di Carlo F, Pettorruso M, Guirguis A, Corkery JM, Martinotti G, Schifano F, Di Giannantonio M. Misuse of Anticholinergic Medications: A Systematic Review. Biomedicines. 2022 Feb 1;10(2):355. doi: 10.3390/biomedicines10020355. PMID: 35203563; PMCID: PMC8962297.
6. Yohn SE, Weiden PJ, Felder CC, Stahl SM. Muscarinic acetylcholine receptors for psychotic disorders: bench-side to clinic. Trends Pharmacol Sci. 2022 Dec;43(12):1098-1112. doi: 10.1016/j. tips.2022.09.-006. Epub 2022 Oct 20. PMID: 36273943.
7. Herschman ZJ, Silverstein J, Blumberg G, Lehrfield A. Central nervous system toxicity from nebulized atropine sulfate. J ToxicolClinToxicol. 1991;29(2):273-7. doi: 10.3109/1556 3659109 038621. PMID: 2051513.
8. Basha SA, Sathiswara B. Atropine induced psychosis: a report of two cases. Int J Health Sci Res. 2017; 7(12):325-327.
9. Atropine-Induced Psychosis in Organophosphate (OP) Poisoning Treatment : A Case Report. Ramudu RV, Padmakar S, Harini Y, Shakilamai PS, Ruksana D, Naik MH. J Indian Med Assoc 2025; 123(4): 62-4.
10. Egberts A, van der Craats ST, van Wijk MD, Alkilabe S, van den Bemt PMLA, Mattace-Raso FUS. Anticholinergic drug exposure is associated with delirium and postdischarge institutionali-zation in acutely ill hospitalized older patients. Pharmacol Res Perspect. 2017 May 11;5(3):e00-310. doi: 10.1002/prp2.310. PMID: 28603629; PMCID: PMCID: PMC5464339.
11. Campbell, N., Boustani, M., Limbil, T., Ott, C., Fox, C., Maidment, I., … Gulati, R. (2009). The cognitive impact of anticholinergics: A clinical review. *Clinical Interventions in Aging*, *4*, 225–233. https://doi.org/10.2147/cia.s5358
12. Das S, Chatterjee SS, Malathesh BC. Anticholinergic medications even in therapeutic range can cause recurrence of psychosis. Gen Psychiatr. 2020 Jul 19;33(4):e100235. doi: 10.1136/gpsych-2020-100235. PMID: 32783023; PMCID: PMC7371018.
13. Trenkwalder C, Paulus W. Restless legs syndrome: pathophysiology, clinical presentation and management. Nat Rev Neurol. 2010 Jun;6(6):337-46. doi: 10.1038/nrneurol. 2010.55. PMID: 20531433.
14. Garcia-Borreguero D, Larrosa O, Williams AM, Albares J, Pascual M, Palacios JC, Fernandez C. Treatment of restless legs syndrome with pregabalin: a double-blind, placebo-controlled study. Neurology. 2010 Jun 8;74(23):1897-904. doi: 10.1212/WNL. 0b013e3181e1ce73. Epub 2010 Apr 28. PMID: 20427750.
15. Mancini V, Latreche C, Fanshawe JB, Varvari I, Zauchenberger CZ, McGinn N, Catalan A, Pillinger T, McGuire PK, McCutcheon RA. Anticholinergic Burden and Cognitive Function in Psychosis: A Systematic Review and Meta-Analysis. Am J Psychiatry. 2025 Apr 1;182(4):349-359. doi: 10.1176/appi.ajp. 20240260. Epub 2025 Feb 26. PMID: 40007252.

Review Article

Prosthodontic Management of Fractured Implant and Components: A Literature Review

Akshat Srivastava, Shitij Srivastava, Abhinav Shekhar, Love Kumar Bhatia
Department of Prosthodontics and Crown & Bridge, Sardar Patel Post Graduate Institute of Dental and Medical Sciences, Lucknow (Uttar Pradesh)

ABSTRACT:
Dental implants have revolutionized prosthodontic rehabilitation, offering reliable long-term solutions for edentulism. However, mechanical complications such as implant or component fractures, though relatively rare, present significant challenges for clinicians. Fractures can involve the implant body, abutment screw, or prosthetic components, often resulting from biomechanical overload, design flaws, material fatigue, or improper occlusion. Timely diagnosis and appropriate management are crucial to preserve peri-implant health and restore function and esthetics. Non-invasive retrieval techniques, such as screw removal kits, ultrasonic vibration, or trephining, are considered based on the fracture location and severity. In cases where removal is impractical, the fractured implant may be left in situ, and alternative implant placement considered. This literature review explores the etiology, clinical presentation, and prosthodontic strategies for managing fractured implants and associated components and also emphasizes the importance of preventive measures. Understanding fracture patterns and material behavior is key to improving long-term success rates.

KEYWORDS: Implant fracture, abutment screw fracture, implant complications, retrieval techniques, implant re-treatment.

Address for correspondence : Dr. Akshat Srivastava, Post Graduate Student, Department of Prosthodontics and Crown & Bridge, Sardar Patel Post Graduate Institute of Dental and Medical Sciences, Lucknow - 226029 (Uttar Pradesh) - India.
E-mail: akshat.srivastava.bds@gmail.com
Submitted: 28.05.2025, **Accepted:** 05.09.2025, **Published:** 26.12.2025

INTRODUCTION:

Dental implants have become a widely accepted and predictable treatment modality for the replacement of missing teeth. However, like any biomedical device, they are not devoid of complications. Among these, mechanical complications such as fractures of the implant body, abutment, or screws represent significant challenges in prosthodontic practice. A thorough understanding of the etiology, prevention, and management strategies is essential. This review aims to provide an evidence based overview of the prosthodontic management of fractured implants and associated components.

Access this article online

Quick Response Code:	Website: www.pjsr.org
	DOI: https://doi.org/10.5281/zenodo.18060127

Implant Fracture: Implant fractures are defined as structural failures of the implant body or its components, compromising the integrity and function of the implant-supported prosthesis. Fractures are generally classified as:

- Implant body fractures: Complete or partial breakage of the implant fixture.
- Abutment fractures: Separation or breakage of the abutment screw or body.
- Screw fractures: Thread or head fractures, often resulting in loosening or complete detachment of the prosthesis.

Classification systems such as those proposed by Goodacre et al. further divide complications into

This is an open access journal, and articles are distributed under the terms of the Creative Commons Attribution-Non Commercial ShareALike 4.0 License, which allows others to remix, tweak, and build upon the work non-commercially, as long as appropriate credit is given and the new creations are licensed under the identical terms.
For reprints contact: editor.pjsr@peoplesuniversity.edu.in

How to cite this article: Srivastava A, Srivastava S, Shekhar A, Bhatia LK. Prosthodontic Management of Fractured Implant and Components: A Literature Review. PJSR. 2025;18(2):56e.

Table 1: Types of Implant and Component Fractures.

Type of Fracture	Location	Common Causes	Clinical Implications
Implant Body Fracture	Within the implant fixture	Excessive occlusal load, material fatigue	Requires complete removal and replacement
Abutment Fracture	Between fixture and prosthetic	Improper fit, excessive torque	Cansometimesbe repaired
Screw Fracture	Within the abutment screw	Insufficient preload, repeated loading	Risk of implant loosening
Prosthetic Fracture	Crown or bridge on implant	Material weakness, malocclusion	Often requires prosthetic replacement

biological and mechanical, with fractures forming a subset of the mechanical type[1].

Etiology of Implant and Component Fracture:-

Several factors contribute to implant and component fractures, which can be broadly categorized as follows:

1. Biomechanical Overload: Excessive occlusal forces from parafunctional habits (e.g., bruxism), inadequate occlusal design, and misaligned implant positioning increase the risk of stress accumulation leading to fracture[2].

2. Material Fatigue: Cyclic loading over time can cause microcracks and eventual failure in titanium or zirconia implants, especially under tensile or bending stresses[3].

3. Prosthetic Factors: Improper torque values, poor fit of prosthetic components, and suboptimal screw joint designs can lead to screw loosening and subsequent fracture[4].

4. Surgical Factors: Poor bone quality, over-preparation of the implant site, and misalignment can create a biomechanically unfavorable environment contributing to implant failure[5].

Implant body fractures are situated within the implant fixture and typically result from excessive occlusal load or material fatigue; these fractures usually require complete removal and replacement of the implant. Abutment fractures occur between the fixture and prosthetic components, often due to improper fit or excessive torque, and may sometimes be repaired depending on severity. Screw fractures are found within the abutment screw, commonly arising from insufficient preload or repeated loading, and they pose a risk of implant loosening. Lastly, prosthetic fractures affect crowns or bridges placed on implants, which can arise from material weaknesses or malocclusion and generally necessitate replacement of the prosthetic restoration. This is illustrated in Table 1.

Diagnosis of Implant Component Fractures Fractures are diagnosed using a combination of clinical and radiographic assessments:-

A thorough clinical examination is a cornerstone of diagnosing fractured dental implants and their components. Identifying fractures, assessing implant stability, and evaluating the surrounding soft and hard tissues are essential steps in determining the appropriate treatment plan. The clinical examination of a patient with a potential fractured implant or component involves a systematic approach that includes patient history, physical inspection, functional testing, and assessment of associated tissues[6].

Patient History and Complaint: A detailed patient history plays a crucial role in the diagnosis of fractured implants and components. The history should focus on the onset of symptoms, functional problems, and any related risk factors. Common complaints related to fractured implants and components include pain, swelling, implant mobility, and difficulty with chewing. Patients may complain of mobility or a loose prosthesis, which can be indicative of an implant fracture or screw loosening.

PHYSICAL INSPECTION:-

The dentist should look for obvious signs of damage or failure, such as visible cracks in the crown, abutment loosening, or metallic exposure.

Key aspects of the physical examination include:

- **Soft Tissue Assessment**: The condition of the surrounding mucosa should be evaluated for signs of gingival recession, inflammation, infection, or peri- implantitis. Healthy peri-implant tissues should appear pink, firm, and without signs of bleeding on probing.
- **Prosthesis and Abutment Examination**: Visual inspection of the implant crown, abutment, and

screw connection for signs of fractures, chipping, or looseness should be done. Fractured components may present as visible cracks, chips, or even complete dislodgement from the implant.

- **Occlusion Evaluation**: A thorough occlusal examination should be performed to assess the implant's function during chewing and occlusal contact. Malocclusion or excessive forces may indicate the potential for component failure.

PALPATION AND PERCUSSION:-

- ***Palpation:*** Gently palpate around the implant site to check for implant mobility or soft tissue inflammation. Periapical tenderness or abnormal movement in the implant can indicate implant fracture or loosening of the abutment or screw**.**
- ***Percussion***: Percussion testing can help assess the stability of the implant. Tapping on the implant with a dental instrument may help detect implant mobility or the presence of cracks in the implant or components. A positive percussion test may suggest implant instability, which could be due to fracture or loosening.
- ***Functional Testing*:** involves evaluating the ability of the implant to bear load during activities such as chewing and biting. This test can help assess the implant's functional capacity and identify any abnormalities or discomfort.
- **Load Testing**: The patient is asked to bite down or chew on a test object to assess the implant's response to occlusal forces. Abnormal pain, discomfort, or implants that shift or move under pressure may indicate fractures or screw loosening.
- **Mobilization Test**: If the implant shows signs of mobility during palpation, further testing is needed to assess the degree of mobility. Mobility could be indicative of implant failure or loosening of the connection between the implant and prosthetic component.

IMPLANT STABILITY ASSESSMENT:-

Implant stability is a key factor in diagnosing fractures and failures.

- ***Periotest*:** A non-invasive test that measures the resonance frequency of the implant. A low resonance frequency indicates reduced stability, which may be due to implant fracture or failure.
- ***Implant Mobility*:** Clinical mobility is assessed by gently trying to move the implant in the buccolingual or mesiodistal direction. Perceived movement indicates implant failure, which may be caused by fracture or poor osseointegration.
- ***Torque Measurement*:** In cases where screws or abutments are suspected to be loose or fractured, torque measurement devices can assess the force needed to tighten or loosen the components, helping to identify the nature of the fracture.

RADIOGRAPHIC IMAGING:-

Radiographic imaging is an essential tool in diagnosing fractures, loose components, and peri-implant bone loss. Common imaging modalities include:

- **Periapical X-rays**: Conventional periapical radiographs are used to assess the status of the implant-bone interface and identify any bone loss around the implant. Fractures in the implant body or the abutment may also be visible on these images.
- **Cone Beam Computed Tomography (CBCT)**: CBCT offers a 3D view of the implant site, allowing clinicians to evaluate the implant position, bone quality, and implant stability. This imaging method is particularly useful for detecting microfractures or subtle fractures that may not be visible on conventional X- rays.

Management Strategies: The management of fractured implant components is complex and depends on the type, location, and severity of the fracture. They may be non-invasive or invasive techniques.

Screw Fracture Management: Screw Fracture where the screw is unable to be retrieved at all, it leads to the removal of entire implant from the bone, making the procedure invasive

a. ***Retrieval of Fractured Screw*:**

- Conventional methods: Use of ultrasonic scalers, explorers, and screw retrieval kits.
- Modified techniques: Creating a slot in the screw and using a flathead driver to turn it out counterclockwise.
- Commercial kits: Examples include the Safe Relax system and the ITI Retrieval Kit [7].

b**.** ***Non-Retrievable Screw:*** In cases where screw retrieval fails, removal of the entire implant or conversion to a cement-retained prosthesis may be required[8].

Abutment Fracture Management: Abutment Fracture can be managed non-invasively.

Table 2: Comprehensive approach to temporary management

Temporary Management Approach	Material Used	Outcome/Benefits
Splinting	Dental resin, acrylic	Stabilizes loose or displaced components
Temporary Crowns	Acrylic, composite	Restores appearance and function temporarily
Occlusal Adjustments	No material required	Reduces stress on fractured components
Temporary Implant Replacement	Titanium, temporary crowns	Restores function, protects space

- Replace the fractured abutment if the internal implant connection is intact.
- Evaluate the need for custom abutments for better force distribution.
- Use torque control devices to ensure appropriate loading.

If the abutment fracture causes damage to the internal implant threads, removal or retrofitting of the prosthesis may be necessary[9].

Implant Body Fracture Management: -

This represents the most severe form and often necessitates surgical intervention making it invasive.

- Non-salvageable fractures: Complete removal of the fractured implant using trephine burs.
- Salvageable cases: When only a portion of the implant is fractured, a shorter abutment can be used if the remaining portion is stable[10].

Subsequent bone grafting and delayed implant placement may be required, depending on the defect size.

Prosthodontic Considerations for Fracture Prevention:-

The prosthodontist plays a pivotal role in the prevention of implant fractures through careful planning and execution.

The temporary management of fractured implants and components can be approached through different provisional strategies. These include splinting, which uses dental resin or acrylic materials to stabilize loose or displaced implant components; the use of temporary crowns made of acrylic or composite to restore appearance and function on a short-term basis; occlusal adjustments without additional materials to reduce stress on fractured parts; and temporary implant replacement utilizing titanium and temporary crowns to restore function and protect the implant space during healing or treatment phases. Each of these methods offers specific clinical benefits, such as stabilization, protection, and maintenance of esthetics and function while definitive treatment planning or healing occurs[11]. This is illustrated in Table 2.

1. ***Occlusal Considerations***: Occlusal considerations are important in implant therapy because implants respond differently to bite forces than natural teeth. Proper occlusion helps distribute biting forces evenly, preventing overload that can cause implant bone loss, prosthesis failure, or screw loosening. Guidelines recommend designs that minimize stress on implants, such as using mutually protected occlusion, reducing cantilever length, and selecting strong materials for prostheses. Regular occlusal checks and adjustments help maintain implant health and prevent complications, ultimately extending the implant's lifespan.
   - Establishment of a mutually protected occlusion.
   - Elimination of interferences in lateral or protrusive movements.
   - Use of occlusal guards in bruxism patients[12].
2. ***Prosthesis Design***:
   - Splinting of multiple implants to distribute forces evenly.
   - Avoiding cantilevers or limiting their extension.
   - Choosing appropriate materials for the superstructure that absorb stress (e.g., PEEK, composite resins).
3. ***Implant Selection and Placement***:
   - Use of wider or longer implants in areas with high occlusal loads.
   - Placement in positions that align with the long axis of the prosthesis.
   - Use of implants with internal connections to improve force distribution[13].
4. ***Maintenance Protocols***:
   - Regular follow-up appointments to detect early signs of screw loosening or prosthesis mobility.
   - Patient education on avoiding excessive forces.

Emerging Technologies and Techniques:-

Recent advancements aim to minimize mechanical complications:

Table 3: Implant removal Method.

Implant Removal Method	Indications	Advantages	Disadvantages
Rotational Instruments	Implant has fractured above the bone level	Minimally invasive, quicker procedure	May not be effective in deeply embedded implants
Trephine Bur	Implant deeply embedded in bone	Allows for removal of deeply integrated implants	Risk of bone damage, may require bone grafting
Surgical Flap Approach	In cases of implants with significant tissue damage	Provides excellent access to the implant site	More invasive, requires flap closure and post-operative care
Ultrasonic Devices	Fractured implants in hard-to-reach locations	Precise, less traumatic to surrounding tissues	High cost, requires specialized equipment

Table 4: Bone Grafting Technique.

Bone Grafting Technique	Indications	Advantages	Disadvantages
Autografts	Significant bone loss, optimal biological compatibility	No risk of disease transmission, excellent healing	Limited donor site, invasive, longer recovery
Allografts	Moderate bone loss, non-invasive	Readily available, less invasive	Risk of disease transmission, slower integration
Xenografts	Larger defects, long-term restoration	Biocompatible, effective for larger defects	Slower healing, limited incorporation into host bone
Alloplastic Materials	Small bone defects, less expensive	No risk of disease transmission, easy to handle	Less predictable, may not integrate as well as other graft types

- **Digital implant planning** and guided surgery ensure optimal placement.
- **CAD/CAM abutments** provide precise fit and improved stress distribution.
- **Smart implants** with embedded sensors can detect early biomechanical failures.

Nanotechnology and surface modifications are also being explored to enhance implant durability[15].

Laser-assisted procedures have become increasingly popular in the restoration of fractured implants, particularly for soft tissue management around the implant site. Lasers can help in reshaping the gum tissue, improving aesthetics, and providing a more comfortable experience for the patient during restorative treatments. They are also used for decapping or removal of fractured abutments.

Surgical Considerations in the Management of Fractured Implants and Components:

Surgical intervention is often necessary when a fractured implant or its components cannot be managed conservatively. This may include situations where the implant itself has fractured or where the damage to the prosthetic components (such as abutments or crowns) is severe. Surgical techniques for the management of fractured implants and components vary depending on factors such as implant location, degree of fracture, bone condition, and surrounding soft tissue health. The goal of surgical management is to restore function, preserve bone, and minimize any aesthetic compromise. This section outlines various surgical approaches, techniques, and their outcomes, providing an in-depth understanding of the surgical management of fractured implants and components[16].

Removal of Fractured Implants:

When a fractured implant cannot be salvaged, the first step is implant removal. This procedure requires careful planning and execution to avoid causing additional damage to the surrounding bone and soft tissues. Several methods can be employed depending on the implant fracture's severity and the surrounding anatomical features.

Implant removal methods depend on the fracture location and implant status. Rotational instruments are used for fractures above bone level, offering a minimally invasive, quicker procedure but may be ineffective for deeply embedded implants. Trephine burs are preferred for deeply integrated implants as they allow removal but carry a risk of bone damage and may require bone grafting. Surgical flap approaches provide excellent access in cases with significant tissue damage but are more invasive and require flap closure and post-operative care. Ultrasonic devices enable precise, less traumatic removal of fractured implants in hard-to-reach areas, though they come with high costs and require specialized equipment[17]. This is illustrated in Table 3.

A thorough clinical and radiographic assessment is done to evaluate the implant position, fracture extent, and bone quality.

Bone Grafting and Site Preparation:

In many cases, implant removal leads to a defect in the surrounding bone, especially if the implant has been in place for a long period. This is often the case with large implant fractures or when poor osseointegration is present. Bone grafting procedures are essential to restore the bone volume and provide a stable foundation for a new implant.

Bone grafting is often required following implant removal to restore lost bone volume. Autografts are indicated for significant bone loss, offer optimal biological compatibility, and excellent healing, but involve invasive procedures and limited donor site availability. Allografts are used for moderate bone loss, are less invasive, and readily available but carry a risk of disease transmission and slower integration. Xenografts suit larger defects and long-term restoration due to biocompatibility but also heal slower and incorporate less fully. Alloplastic materials are preferred for small defects as they are inexpensive and easy to handle but tend to integrate less predictably than biological grafts[18]. This illustrated in Table 4.

Surgical Techniques for Managing Fractured Components:-

In cases where the prosthetic components (e.g., abutments, screws) have fractured but the implant remains intact, surgical intervention may still be required to access the fractured component and remove it. The most common surgical techniques for this scenario involve creating a flap to access the damaged components.

Flap Surgery for Component Removal:

Flap surgery may be necessary to access and retrieve fractured components that cannot be removed with conventional methods. A well-planned flap approach ensures minimal damage to the surrounding tissues while allowing for effective access to the fractured part.

Prognosis and Long-Term Outcomes:

The prognosis depends on early detection, appropriate intervention, and adherence to prosthodontic principles. Studies suggest that mechanical complications such as screw fractures are relatively common (2%–10%) but manageable if addressed promptly. Implant body fractures, while rare (<1%), often require surgical removal and are associated with greater morbidity[19].

Preventive Strategies:

The prevention of implant fractures and component failure is a crucial aspect of successful prosthodontic treatment. Preventive strategies aim to reduce the likelihood of complications and extend the lifespan of dental implants and their components. These strategies encompass a wide range of factors, including patient education, proper implant placement, maintenance protocols, and the use of preventive materials. By addressing these factors early in the treatment process, the risk of failure due to occlusal overload, infection, or material fatigue can be significantly minimized.

Patient Education:

A key element in the prevention of implant-related complications is patient education. Patients must understand the importance of maintaining oral hygiene, following post- surgical care instructions, and adhering to routine check-ups. Proper patient education can also help in minimizing habits such as bruxism or clenching, which are significant risk factors for implant fractures. The following educational aspects should be emphasized:

- ***Oral Hygiene***: Proper cleaning and maintenance around implants are vital to preventing peri-implantitis and implant failure. Patients should be taught effective brushing techniques and the use of interdental brushes or floss to keep the area around the implant free from bacterial accumulation.
- ***Avoiding Excessive Force***: Bruxism and clenching should be identified early, and appropriate measures, such as the use of night guards or occlusal splints, should be suggested.
- ***Regular Check-ups***: Periodic follow-ups with the dentist are necessary to monitor the condition of the implant and components, identify early signs of complications, and intervene before significant damage occurs.

CONCLUSION:

Fractures of dental implants and their components present significant clinical challenges that necessitate a multidisciplinary approach. Prosthodontists must be well-versed in identifying the causes, managing complications, and implementing strategies for prevention. Through careful planning, proper occlusal design, and regular maintenance, the risk of such complications can be significantly reduced, ensuring long-term success and patient satisfaction.

Financial Support and Sponsorship

Nil.

Conflicts of Interest

There are no conflicts of interest.

REFERENCES:

1. Goodacre CJ, Bernal G, Rungcharassaeng K, Kan JY. Clinical complications with implants and implant prostheses. J Prosthet Dent. 2003 Aug;90(2):121-32. doi: 10.1016/S0022-3913(03)00212-9. PMID: 12886205.
2. Rangert B, Jemt T, Jörneus L. Forces and moments on Branemark implants. Int J Oral Maxillofac Implants. 1989 Fall;4(3):241-7. PMID: 2700747.
3. Binon PP. Implants and components: entering the new millennium. Int J Oral Maxillofac Implants. 2000 Jan-Feb;15(1):76-94. PMID: 10697942.
4. Naconecy MM, Teixeira ER, Shinkai RS, Frasca LC, Cervieri A. Internal vs external connections: a mechanical analysis. Braz Dent J. 2006;17(1):10–4. doi: 10.5958/0974-360X.2017.00167.6
5. Esposito M, Hirsch JM, Lekholm U, Thomsen P. Biological factors contributing to failures of osseointegrated oral implants. (II). Etiopathogenesis. Eur J Oral Sci. 1998 Jun;106(3):721-64. doi: 10.1046/j.0909-8836..t01-6-.x. PMID: 9672097.
6. Murakami H, Igarashi K, Fuse M, Kitagawa T, Igarashi M, Uchibori S, Komine C, Gotouda H, Okada H, Kawai Y. Risk factors for abutment and implant fracture after loading. J Oral Sci. 2020 Dec 23;63(1):92-97. doi: 10.2334/josnusd.20-0443. Epub 2020 Dec 14. PMID: 33311012.
7. Bozkaya D, Müftü S. Mechanics of the tapered interference fit in dental implants. J Biomech. 2003 Nov;36(11):1649-58. doi: 10.1016/s0021-9290(03)00177-5. PMID: 14522206.
8. Schwarz MS. Mechanical complications of dental implants. Clin Oral Implants Res. 2000;11Suppl 1:156-8. doi: 10.1034/j.1600-0501.2000.011s1156.x. PMID: 11168264.
9. Brägger U, Krenander P, Lang NP. Economic aspects of single-tooth replacement. Clin Oral Implants Res. 2005 Jun;16(3):335-41. doi: 10.1111/j.1600-0501.2005.01112.x. PMID: 15877754.
10. Wiskott HW, Belser UC. Lack of integration of smooth titanium surfaces: a working hypothesis based on strains generated in the surrounding bone. Clin Oral Implants Res. 1999 Dec;10(6):429-44. doi: 10.1034/j.1600-0501.1999.100601.x. PMID: 10740452.
11. Bein L, Rauch A, Schmidt M, Rosentritt M. In vitro fatigue and fracture testing of temporary materials from different manufacturing processes in implant-supported anterior crowns. Clinical Oral Investigations. 2023 Aug;27(8):4215-24.doi: 10.1111/prd.12416. PMID: 35103329; PMCID: PMC9305548.
12. Stilwell C. Occlusal considerations in maintaining health of implants and their restorations. British Dental Journal. 2024 May 24;236(10):773-9.
13. Misch CE. Occlusal considerations for implant-supported prostheses: implant protected occlusion. *Implant Dent*. 1993;2(4):282–94. DOI:10.1016/B978-0-323-07845-0.00031-2
14. Geng JP, Tan KB, Liu GR. Application of finite element analysis in implant dentistry: a review of the literature. J Prosthet Dent. 2001 Jun;85(6):585-98. doi: 10.1067/mpr.2001.115251. PMID: 11404759.
15. Berglundh T, Persson L, Klinge B. A systematic review of the incidence of biological and technical complications in implant dentistry reported in prospective longitudinal studies of at least 5 years. J ClinPeriodontol. 2002;29Suppl 3:197-212; discussion 232-3. doi: 10.1034/j.1600-051x.29.s3.12.x. PMID: 12787220.
16. Masaki C, Kondo Y, Tomoeda K, Nodai T, Munemasa T, Mukaibo T, Hosokawa R. Treatment strategies for dental implant removal: A literature review. Japanese Dental Science Review. 2024 Dec 1;60:120-7.https://doi.org/10.1016/j.jdsr.2024.01.002
17. Chittavoravanich N, Jirajariyavej B, Bencharit S, Thanasrisuebwong P. Comparison of Four Different Dental Implant Removal Techniques in Terms of the Weight and Volume of Bone Loss. Cureus. 2024 May 26;16(5):e61104. doi: 10.7759/cureus.61104. PMID: 38919230; PMCID: PMC11197631.
18. Liñares A, Dopico J, Magrin G, Blanco J. Critical review on bone grafting during immediate implant placement. Periodontol 2000. 2023 Oct;93(1):309-326. doi: 10.1111/prd.12516. Epub 2023 Sep 1. PMID: 37658586.
19. Jung RE, Zembic A, Pjetursson BE, Zwahlen M, Thoma DS. Systematic review of the survival rate and the incidence of biological, technical, and aesthetic complications of single crowns on implants reported in longitudinal studies with a mean follow-up of 5 years. Clin Oral Implants Res. 2012 Oct;23Suppl 6:2-21. doi: 10.1111/j.1600-0501.2012.02547.x. PMID: 23062124.

Review Article

Significance of Orofacial Manifestations Associated with Anemia: A Review

Sahil Kohli[1], **Christopher Vinay Shinde**[2], **Vini Shinde**[3]

[1]Department of Oral Medicine and Radiology, [1]RKDF Dental College and Research Centre, Bhopal, [2]People's Dental Academy, People's University, Bhopal (Madhya Pradesh), [3]Department of Oral Pathology and Microbiology, People's Dental Academy, People's University, Bhopal (Madhya Pradesh)

ABSTRACT:

When there is decrease in total erythrocyte count and oxygen carrying tendency of blood, it results in anemia. The common clinical features include fatigue, weakness and pallor. The oral cavity is affected by this disease and the common sites are labial mucosa, gingiva, tongue, periodontium and dentition. Oral findings include changes in the oral mucosa, periodontal inflammation, angular cheilitis, glossitis, mucosal ulceration and dental anomalies. According to World Health Organization (WHO),one third of the world population suffers from anemia because of improper food consumption and improper nutrition. Careful assessment should be done to recognize the oral manifestations of this disease, so that correct diagnosis can be done.

KEY WORDS: anemia, hemoglobin, iron, deficiency, blood

Address for correspondence : Dr. Sahil Kohli, Reader, Department of Oral Medicine and Radiology, RKDF Dental College and Research Centre, Bhopal (Madhya Pradesh) , India, E-mail: sahilkohlisk11@gmail.com

Submitted: 04.08.2025, **Accepted:** 10.10.2025, **Published:** 26.12.2025

INTRODUCTION:

Anemia is a disease in which there is decrease in the total hemoglobin level. In this disease, the number of red blood cells are decreased.[1]The decrease in the total erythrocyte count causes reduction in the oxygen carrying tendency of blood and it results in hypoxia of the body tissues. According to World Health Organization (WHO), almost one third of the world population suffers from anemia because of improper nutrition. In India, about 80% of maternal deaths occur due to this disease.[2] When the hemoglobin level is less than 13 gm/dl (grams per deciliter) in males and less than 12 gm/dl in females, it results in anemia. According to an estimation done by WHO, 293 million children globally are suffering from this disorder and almost half of them are because of deficiency of iron. The clinical features include fatigue, pallor and dyspnea.[3] Blood loss due to trauma or internal bleeding, diseases such as malaria and autoimmune diseases can cause anemia.[4]

Access this article online

Quick Response Code:	Website: www.pjsr.org
	DOI: https://doi.org/10.5281/zenodo.18060463

OROFACIAL MANIFESTATIONS ASSOCIATED WITH ANEMIA:

Sickle Cell Anemia-

Sickle cell anemia is a chronic, hemolytic blood disorder. In this autosomal recessive disorder, there is sick ling of red blood cells due to presence of deoxygenated hemoglobin under decreased oxygen tension.[5] There is homozygous state of abnormal hemoglobin S which causes change in the DNA(deoxyribonucleic acid) molecule. There is replacement of the amino acid valine for glutamic acid.[6] There is polymerization of abnormal hemoglobin which leads to the production of tactoids, which are fluid polymers. The red blood cells attain sickle shape. There is ischemic tissue injury due to chronic hemolytic anemia and vasoocclusion.[7[The membrane lipids of the blood cells are destroyed which leads to decrease in

This is an open access journal, and articles are distributed under the terms of the Creative Commons Attribution-Non Commercial ShareALike 4.0 License, which allows others to remix, tweak, and build upon the work non-commercially, as long as appropriate credit is given and the new creations are licensed under the identical terms.
For reprints contact: editor.pjsr@peoplesuniversity.edu.in

How to cite this article: Kohli S, Shinde CV, Shinde V. Significance of Orofacial Manifestations Associated with Anemia: A Review. PJSR. 2025;18(2):63e

the supply of oxygen to the tissues and obstruction of capillaries as these damaged cells attach to vascular endothelium. The destruction of these cells by the spleen takes place.[5] The clinical features are observed between 6 months and 3 years of age. The sickle shaped cells are C shaped, rigid and sticky and cause the formation of clumps. But the initiation of features is delayed because of the protection provided by fetal hemoglobin.[6] Hyperbilirubinemia can take place. Clinical features include fatigue, irritation, tachycardia, shortness of breath and dizziness.[8] Fever, joint pain, muscle pain and weakness can occur. Hyperplasia of bone marrow and thinning of cancelloustrabeculae is common in such cases.[5] There can be increased thickening of the skull due to widening of the diploicspace, mandibular infarction, osteomyelitis of the mandible, bonesclerosis, paresthesia of the mental nerve, necrosis of pulp, pain in the orofacialregion, diastema and hypomineralization of the enamel can be observed in such patients. Radiographic features include step ladder shape of the alveolar bone and osteoporosis, due to reduction in the volume of trabecular bone. There is pain in the mandible, neuropathy involving inferior alveolar nerve and paresthesia of lower lip in such patients.[7] Mucosal pallor and jaundice is common. Thinning of cortical plate and diminished trabeculation can be seen radiographically. The inferior border of mandible loses its normal shape. There can be presence of denticle like calcified bodies in dentinal tubules and pulp chambers. Delayed eruption of teeth, enamel hypoplasia and dentin hypoplasia can occur, which can further lead to development of dental caries in such patients.[8]

On analyzing orofacial manifestations of sickle cell disease, it was found that mucosal pallor and jaundice is common in such patients due to early breakdown of red blood cells in the spleen. The decreased number of red blood cells can cause hemolytic anemia and hyperbilirubinemia. Gingiva,buccal mucosa and labial mucosa undergo discoloration in such patients. A microradiography study of dental tissues was conducted in such patients and it was observed that there were hypomineralized and diffused areas present in the tooth enamel. The presence of calcified structures in pulp chambers was also observed in the study.[8] The portion of enamel, which had undergone hypocalcification, would allow the development of cariogenic bacteria as these bacteria are connected to the base of the defects and are close to exposed dentin, thus leading to the development of dental caries in such patients. Fakuda et al conducted a study and observed that if patients, suffering from sickle cell disease, are given penicillin prophylaxis for a long time, it delays the acquisition of *Streptococcus Mutans*, thus, decreasing the risk of development of dental caries in such patients. Vaso-occlusive crisis can occur in such patients, due to disturbance of microcirculation in the pulp causing pulp necrosis. Blood thrombosis can cause calcified pulp stones in the pulp chamber.[8] There can be presence of radiopaque areas caused by repairs to bone infarction. Coarse trabecular pattern of staircase shape can be observed in the interproximal bone. Radiolucency can be observed due to decreased trabeculae and increased medullary spaces secondary to compensatory hyperplasia.[6]

In cases of mildly anxious patients, the treatment includes pain management anxiolytics and sedatives. Nitrous oxide gas also helps in reducing anxiety in patients undergoing dental treatment but in cases of severe anxiety, general anesthesia should be given. If such patients are suffering from infections then antibiotic therapy should be given. Acetaminophen is advised for pain relief in such patients as salicylates can cause acidosis.[8] In 1980, Konotey-Ahulu observed a disorder, known as mental nerve neuropathy, in such patients. In this disorder, vasculo-occlusion can occur in the maxillofacial region and can cause infarction of the blood supply to the nerves, which are mental nerve and inferior alveolar nerve. This can lead to loss of sensation, persistent anesthesia and neuropathy in lower lip and chin and this condition can continue upto 24 months. During sickle cell crisis, it was found that 4% of the patients complained of pain in mandible which varied in severity from moderate to severe. The development of burning sensation and numbness of lower lip occurred in such patients and the condition continued for months. The signs and symptoms developed along the path of mental nerve in such patients. In another case, a 40 year old male patient complained that his right mandibular first premolar, canine and incisors felt like wooden blocks.

After conducting a needle prick test, it was observed that profound anesthesia had developed in areas supplied by mental nerve. On radiographic analysis of right mental nerve, it was found that an ovoid radiolucency was present as a result of decreased trabeculation. It could also be due to sickle cell crisis causing production of acute bony infarct of the mandible. A follow up for 12 months was conducted, during which the pain disappeared but loss of sensation in the lower lip was present. No changes in the radiographic findings was observed.[8]

Iron deficiency anemia:

Iron deficiency anemia results from insufficient

iron in the normal red blood cells. Hepcidin is a hormone that is generated in the liver and it stops absorption of iron from intestine.[9] Iron is an important constituent of hemoglobin protein, helps in the movement of electrons within the cell, and helps in oxygen enzyme reactions.[10] In this disorder, the iron supply to the bone marrow is decreased and erythropoiesis is disturbed. Low plasma ferrit in and reduction in plasma iron transferrin saturation occurs with decreased hemoglobin.[9] The major causes include less consumption of iron, internal bleeding, blood loss because of menstruation and obstruction in the absorption of iron. Infants, children suffering from malnutrition, females of child bearing age, individuals who consume less iron in diet and people who donate blood multiple times are susceptible to this disorder.[10] The predominant reason of microcytic hypochromic anemia is iron deficiency anemia and mostly infants and children suffer from this disorder. The clinical features include headache, weakness, fatigue and nails of such patients attain spoon shape, which is called koilonychia.[11] Lethargy, tiredness, palpitations and breathlessness can occur.[12] Oral manifestations include glossitis, oral candidiasis, angularcheilitis, recurrent oral ulcers and erythematous mucositis.[3] There can be oral mucosal atrophy, which is generalized, in such patients. There can be angular stomatitis and cheilosis in such patients. Destruction of filiform and fungiform papillae causes atrophic tongue. Burning sensation and glossodyniacan occur in the oral cavity.[7] Iron deficiency anemia is related to Plummer Vinson syndrome and the features include iron deficiency anemia, dysphagia, atrophicglossitis, angularcheilitis, esophageal webs and presence of ulcers in the pharyngoesophageal region.[3] The treatment includes oral and parenteral iron preparations such as ferrous fumarate, ferroussulphate and ferrous gluconate.[13] In cases of fissured tongue, there are several fissures and grooves over the dorsum of the tongue. Many studies have been conducted which showed hereditary association in the etiology of the development of fissured tongue. It can be associated with various syndromes and conditions like Melkersson-Rosenthal syndrome, Acromegaly, Downsyndrome, Sjogren'ssyndrome, Geographictongue, orofacial granulomatosis and psoriasis. Alsheik E et al conducted a study and observed that 24.4% of the Egyptian patients suffering from iron deficiency anemiahave fissured tongue. Mostly such cases are asymptomatic but burning sensation can occur in patients suffering from iron deficiency anemia due to thinning of epithelium of the tongue. Per Lin et al observed that diffusion of spicy salivary elements through the epithelium of tongue, which has undergone atrophy, and their entry into the subepithelial connective tissue causes irritation of free sensory nerve endings. This leads to burning sensation, pain and numbness in the tongue. The presence of glossitis in patients suffering from iron deficiency anemia is indicated as a patchy or diffuse papillae atrophy affecting the dorsum of the tongue. Onhistopathological analysis, hypochromic microcytic cells in a peripheral blood smear can be observed. Such patients have decreased serum ferritin levels and increased Red Cell Distribution Width in the body.[14]

Megaloblastic Anemia-

Vitamin B12 deficiency associated with pernicious anemia, small intestinal diverticula, folic acid deficiency because of malnutrition, or surgical procedure involving ileum, can result in megaloblastic anemia.[7] There are characteristic morphological changes in the precursors of red blood cells.[15] Morphological changes can occur in bone marrow and gastrointestinal tract. Oral manifestations include magenta colouredtongue, recurrentaphthousulcers, glossitis and stomatitis.[7]

In megaloblasticanemia, there is obstruction in DNA formation and obstruction in the progression of the cell cycle. The cells develop abnormally without dividing, which results in megacytosis. Major causes are vitamin B12 deficiency or folic acid deficiency. There is presence of various immature, large and poorly functioning red blood cells, which are known as megaloblasts, in the bone marrow. Vitamin B12 deficiency is characterized by decreased vitamin B12 in blood and it is also called cobalamindeficiency. Common features include initiation of neurological problems, cardiacdisorders, poorreflex, poor muscle function, glossitis and altered taste sensation. Improper gastric or intestinal absorption is one of the major causes. This decreased absorption occurs due to pernicious anemia, which is a type of vitamin B12 deficiency anemia. Loss of intrinsic factors results in disturbed absorption of vitamin B12 as there is damage to gastric parietal cellsin chronic atrophic gastritis and this kind of megaloblastic anemia is called pernicious anemia. The treatment of megaloblastic anemia includes administration of vitamin B12 orally or with the help of injection. In pregnant women, vitamin supplements are advised.[16]

Pernicious Anemia-

Pernicious anemia occurs due to malabsorption of vitamin B12 causing its deficiency. This occurs due to insufficient intrinsic factor, which is important for

normal absorption of vitamin B12, as it leads to production of red blood cells. Therefore, the deficiency causes autoimmune atrophic gastritis.[1] It is an autoimmune disorder in which gradual atrophy of gastric mucosa is observed, which leads to reduction in the number of parietal cells, which is important for absorption of cobalamin, called vitamin B12.[17] The clinical features include breathlessness, fatigue, pain in chest, loss of normal colour of skin, difficulty in coordination and balancing of body, poor reflexes and depression.[4] Oral manifestations include burning sensation in the oral cavity, atrophy of tongue, disturbance in taste sensation, dysphagia and aphthous like ulcerations.[1] Females of more than 50 years of age are mostly affected.[12]

Oral manifestations include Hunter glossitis in which a shiny, erythematous tongue is observed in such patients. The management involves intramuscular injections of cyanocobalamin, hydroxocobalamin or methyl cobalamin. There should be regular evaluation of vitamin B12 levels and iron deficiency in the body. Sometimes administration of intramuscular injection is difficult in elderly patients suffering from sarcopenia and coagulopathy, so oral supplementation is preferred in such cases. In patients suffering from immune driven inflammatory mucosal lesions, the use of topical corticosteroids and low level laser therapy is preferred. In cases such as oral lichen planus, oralmucositis and neuropathic orofacialpain, low level laser therapy, with optical spectral range between 600 and 1100 nm (nanometer) is important for nerve inhibition and pain relief.[17]

Thalassemia-

Thalassemia is also called Cooley's anemia or Mediterranean anemia. It is a hereditary disease and there is improper formation of hemoglobin. There is decrease in hemoglobin and deformed red blood cells with decreased life span.[5] There is fault in the generation of alpha or beta polypeptide chains of hemoglobin. The various forms include homozygous, heterozygous or compound heterozygous.[7] Thalassemia minor is heterozygous type and is mild whereas thalassemia major is homozygous type and is severe, affecting mostly infants. Oraofacial manifestations include abnormally extending premaxilla and bulging cheekbones causing rodent like facial appearance in such patients. There is hyperplasia of the affected bone marrow and expanding of the frontal region of the skull with granular radiographic presentation.[5] Malocclusion,enlargement of maxilla and decrease in cortical dimensions can occur.[7] Large and coarse trabeculae, diminished lamina dura and decreased length of roots can be observed radiographically. There is radiolucency with thickened diploic space.[5] The treatment includes latest medical advances in transfusion, bone marrow transplantation and use of drugs aimed to remove excess iron, known as iron chelators.[18]

In a study involving 54 children and adolescents suffering from Thalassemia Major (which included 31 males, 23 females and thalassemia free controls),it was found that dental caries can occur in such patients, along with poor oral hygiene and gingivitis. The average DMFT value(decayed, missing, filled tooth) was found to be 6.26 for15 year old patients compared with 4.84 in the control group. Poor oral hygiene was present in 61.1% and gingivitis was present in 92.2% of the patients. Orofacial manifestations included chipmunk like face, frontalbossing, saddlenose, discoloration of the dentition, deterioration of labial mucosa, abnormal protrusion of maxilla and discoloration of oral mucosa. Radiographic features included hypoplasia of maxillary sinus, Class II malocclusion, diminished mandibular cortex, thickenedfrontal bone, obstruction in development of teeth and decrease in normal size of teeth. In 75.9% of patients, growth retardation was observed.[18]

Aplastic anemia-

Aplastic anemia is a blood disorder, which is fatal. There is damage to pluripotent stem cells in the bone marrow which leads to peripheral pancytopenia and hypoplastic bone marrow.[2] Clinical features include breathlessness, fatigue, dizziness, headache, pain in chest, abnormal sensation in limbs, paleskin, gingiva and nail beds.[12] Other features associated with neutropenia and thrombocytopenia can be observed in such patients.[2] Oral manifestations include multiple hemorrhages, candidiasis and oral ulceration.[7] Platelet deficiency may cause gingival bleeding, petechialpurpuric spots and mucosal hematomas in the oral cavity. The immunity of the patient is affected which can lead to the development of ulcers in the oral cavity.[2] Treatment for aplastic anemia comprises of blood and marrow stem cell transplants, blood transfusion and medication.[12]

Fanconi Anemia-

Fanconi anemia is an autosomal recessive disorder. The clinical features include bone marrow failure, physical discomfort and susceptibility to malignancy. The presence of café au lait spots, retarded growth, micrognathia, disturbance in functioning of limbs, obstruction in normal physical development of

the body, hyperpigmentation of neck and cardiovascular disorders can be observed in such patients. Oral manifestations include generalizederythroleukoplakia, periodontal problems, dental anomalies and focal ulceration in the oral cavity. The proneness of such patients to oral squamous cell carcinoma is common.[7]

CONCLUSION:

Anemia is a public health problem that results in damaged mental and psychomotor activity, obstruction in normal physical development of children, high rate of child and maternal mortality and high risk of parasitic infections. Nutritional deficiency such as iron deficiency, vitamindeficiency, foliatedeficiency, loss of blood due to hookworm infection, malaria, helminthic infections and low socioeconomic status are some of the causes of anemia. Patient should understand the severity of blood disorders and nutritional deficiencies. The patient should be aware of early signs and symptoms of such diseases. On the basis of various clinical features such as pallor, nailchanges, pedaledema, epithelial changes and diagnostic procedures such as routine blood investigations, bone marrow analysis and peripheral smear examination, an assessment about the diagnosis should be done. There should be proper understanding about the pattern of anemia whether it is acute or its initiation is insidious. Preventive dental therapy should be advised to the patients. Some patients visit dental clinics for emergency treatment rather than preventive care. The dental treatment should never be started during crisis unless it is unavoidable as in emergency cases. Periodic oral health examination every 6 months should be advised to such patients so that comprehensive care can be done.

Financial Support and Sponsorship
Nil.

Conflicts of Interest
There are no conflicts of interest.

REFERENCES:

1. Rao D, Khan M, Rayeen HS, Badyal V, Akhtar N, Iqubal MA. Oral manifestations of anemia: a review. wjpmr 2018;4(2):153-155. file:///C:/Users/user/Downloads/article_1517570161.pdf
2. Anitha N, Appadurai P. Anemia and its oral manifestation. Eur.J.Mol.Clin.Med. 2020;7(8):1715-1719.
3. Anjana, Srivastava R, Mehrotra V, Garg K. Iron deficiency anemia and its oral manifestation-a review. JOAS 2022;1(2):1-6. https://doi.org/10.58935/joas.v1i2.14
4. JohnyJ,NagraleN,Kane S. A review article on anemia. Biosc. Biotech. Res. Comm. 2021;14(7):28-32. https://bbrc.in/wp-content/uploads/2021/07/ Special-Issue-14-7-2021-07.pdf
5. White SC, Pharoah MJ. Oral Radiology:Principles and interpretation. 5th Edn. India:Elsevier;2004.p.533-535.
6. Acharya S. Oral and Dental Considerations in Management of Sickle Cell Anemia. Int J Clin Pediatr Dent. 2015 May-Aug;8(2):141-4. doi: 10.5005/jp-journals-10005-1301. Epub 2015 Aug 11. PMID: 26379384; PMCID: PMC4562049.
7. Gupta S,GuptaS,SwarupN,SairamH,SinhaN,Nair SS. Orofacial manifestations associated with anemia. World J Anemia 2017;1(2):44-47. DOI:10.5005/jp-journals-10065-0010
8. Kakkar M, Holderle K, Sheth M, Arany S, Schiff L, Planerova A. Orofacial Manifestation and Dental Management of Sickle Cell Disease: A Scoping Review. Anemia. 2021 Oct 22;2021:5556708. doi: 10.1155/2021/5556708. PMID: 34721900; PMCID: PMC8556080.
9. Saraswathi Gopal. K, Srividhya.S, Sushmitha.S, Oral Manifestations a Key in Diagnosing Iron Deficiency Anemia–A Case Report, J Res Med Dent Sci, 2021, 9 (4):438-399. https://www.jrmds.in/articles/oral-manifestations-a-key-in-diagnosing-iron-deficiency-anemiaa-case-report.pdf
10. Monga DK, Bhateja S, Arora G. Manifestations, dental considerations and parent's perception of iron deficient anemia in children [Internet]. J Nutr Metab Health Sci. 2019 [cited 2025 Oct 01];2(3):85-88. Available from: https://doi.org/10.18231/j.ijnmhs. 2019.01
11. Chandrasekhar M, Thabusum DA, Charitha M, Chandrasekhar G, Firdous PS. Iron deficiency anemia-a case report with oral manifestations. IBRR 2019;9(2):1-5
12. Soundarya N, Suganthi P. A review on anemia – types, causes, symptoms and their treatments. JOSTI 2016;1:10-17
13. Saxena R, Chamoli S, Batra M. Clinical evaluation of different types of anemia. World J Anemia 2018;2(1):26-30
14. Balamanikandan P, Shetty P, Shetty U. Importance of tongue manifestations in iron deficiency anemia-a

case report. Gal Int J Health Sci Res. 2024;9(2):30-35
15. Teressa H. A review on major causes of anemia and its prevention mechanism. Int J cell Sci & molbiol. 2019;6(3):0057-0062
16. Obeagu EI, Babar Q, Obeagu GU. Megaloblastic anemia-a review. Int J Curr Res Med Sci. 2021;7(5):17-24
17. Boukssim S, Chbicheb S. Oral manifestations of vitamin B12 deficiency associated with pernicious anemia: A case report. Int. J. Surg. Case Rep.2024;1-4
18. Hattab FN. Thalassemia Major and related dentomaxillofacialcomplications: clinical and radiographic overview with reference to dental care. Int J Experiment Dent Sci 2017;6(2):95-104

Case Report

Ameloblastic Fibro-Odontoma - An Insight into its Clinico-Histopathological, Radiographic Features and its Surgical Management

Neha Jain, Ajay K Pillai, Annant Choubey, Amit Kumar Giri
Department of Oral and Maxillofacial Surgery, People's Dental Academy, People's University, Bhopal (Madhya Pradesh)

ABSTRACT:
Ameloblastic fibro-odontoma (AFO) is a rare, benign mixed odontogenic tumor characterized by the presence of epithelial tissue, mesenchymal tissue and dental hard tissues such as enamel and dentin. The lesion is more frequently observed in children and young adults. Clinically, AFO manifests as a painless swelling in the jaw, often associated with impacted or unerupted teeth. Radiographically, it appears as a well-defined, mixed radiolucent-radiopaque lesion. Histologically, it resembles ameloblastic fibroma (AF) with additive formation of enamel and dentin. Treatment generally involves surgical enucleation, with recurrence being rare. We present a case report of a 17 year old female with painless swelling on the left side of mandible, diagnosed with AFO and managed surgically by enucleation.

KEY WORDS: Ameloblastic fibro- odontoma, ameloblastic fibroma, complex odontoma, mixed odontogenic tumors, odontoma

Address for correspondence : Dr. Neha Jain, Professor, Department of Oral and Maxillofacial Surgery, People's Dental Academy, People's University, Bhopal (Madhya Pradesh) , India, E-mail: nehamds26@yahoo.in
Submitted: 24.07.2025, **Accepted:** 15.10.2025, **Published:** 26.12.2025

INTRODUCTION:

Ameloblastic fibro-odontoma (AFO) is an uncommon, benign mixed odontogenic tumor.[1] WHO in 2005 has defined it as a neoplasm composed of proliferating odontogenic epithelium embedded in a cellular ectomesenchymal tissue that resembles dental hard tissues like enamel and dentin.[1] The term AFO was first coined by Hooker in 1967.[2] Prior to 1967 the AFO was confused with ameloblastic-odontoma (odontoameloblastoma) which was aggressive in nature and shared biological behavior with ameloblastoma but in 1967 Hooker distinguished between the two and found it to be less aggressive.[1] The pathology is frequently seen in children between 5-14 years predominantly in molar region.[1,3] Clinical presentation may vary from asymptomatic to symptoms like swelling, delay in eruption of tooth or displacement of teeth and cortical expansion.[4] Radiographically, AFO displays a well-demarcated and encapsulated lesion filled with varying amounts of irregular and haphazardly arranged radiopaque mass mimicking complex odontoma.[2] Histologically it resembles ameloblastic fibroma (AF) with additive formation of enamel and dentin.[2] Due to its benign nature, AFO generally responds well to conservative surgical excision, with a low recurrence rate. This case report demonstrates clinicohistopathological radiographic features of AFO with its management.

CASE REPORT:

A 17 year old female reported to the Department of OMFS, of our institute with chief complaint of painless swelling in her lower left back region of jaws for 6 months. There was no family

Access this article online

Quick Response Code:	Website: www.pjsr.org
	DOI: https://doi.org/10.5281/zenodo.18065864

This is an open access journal, and articles are distributed under the terms of the Creative Commons Attribution-Non Commercial ShareALike 4.0 License, which allows others to remix, tweak, and build upon the work non-commercially, as long as appropriate credit is given and the new creations are licensed under the identical terms.
For reprints contact: editor.pjsr@peoplesuniversity.edu.in

How to cite this article: Jain N, Pillai AK, Choubey a, Giri AK. Ameloblastic Fibro-Odontoma - An Insight into its Clinico-Histopathological, Radiographic Features and its Surgical Management. PJSR. 2025;18(2):69e.

Figure 1: Intraoral picture showing vestibular obliteration.

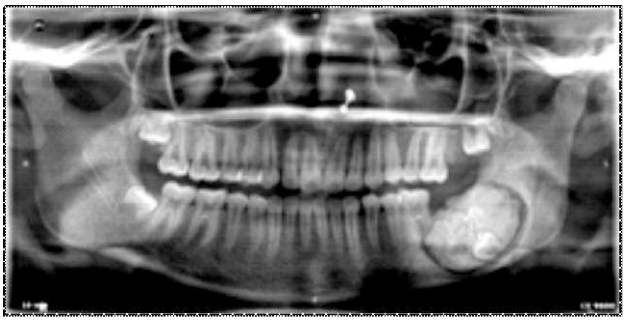

Figure 2: OPG reveals mixed radiopaque, radiolucent mass in the third molar region with unerupted second molar.

history and no past history of trauma or infection. On extraoral examination, facial asymmetry could be noted because of single diffuse swelling 3 cm away from the corner of mouth to the angle of mandible in anterior-posterior direction and superior-inferiorly from the ala tragus line to 1 cm below the lower border of mandible. On intraoral inspection, vestibular obliteration was noticed in the 36, 37, 38 region (Figure 1). Mucosa over the swelling appeared reddish in colour. Missing 37 and 38 were observed. On palpation, swelling was non tender, firm and bony hard in consistency. OPG revealed a well-defined radiopaque lesion extending from distal root of the right 1st molar to the ramus of mandible and an unerupted 37 tooth was observed inside the mass (Figure 2). Root resorption of 36 was evident. CBCT revealed well encapsulated radiopaque lesion measuring 32.1mm x 24.3 mm with expansion of both the buccal and lingual cortical plate and no evidence of cortical plate perforation (Figure 3).

The provisional diagnosis of complex odontoma was made. Differential diagnosis of AFO, calcifying odontogenic cyst, pindborg tumour and odontoamelo-blastoma were made based on the clinical and radiographic presentation.

Figure 3: CBCT revealing well encapsulated lesion with expanded cortices.

The pathological and biochemistry reports (PTH, serum alkaline phosphatase, serum calcium) were within normal range. Considering her age, well encapsulation of the lesion nature and normal biochemistry results, we opted for a conservative enucleation of the lesion.

Under general anesthesia following aseptic protocol, crevicular incision was placed from 34 to 38 region with a vertical relieving incision on the retro molar region. The calcified mass was exposed after elevating the full thickness mucoperiosteal flap. The calcified mass was sectioned into fragments and removed along with the unerupted 37 (Figure 4). The lesion was completely excised and the residual defect margins were smoothened. The specimen was sent for histopathological examination. The inferior alveolar nerve was intact without causing any injury.

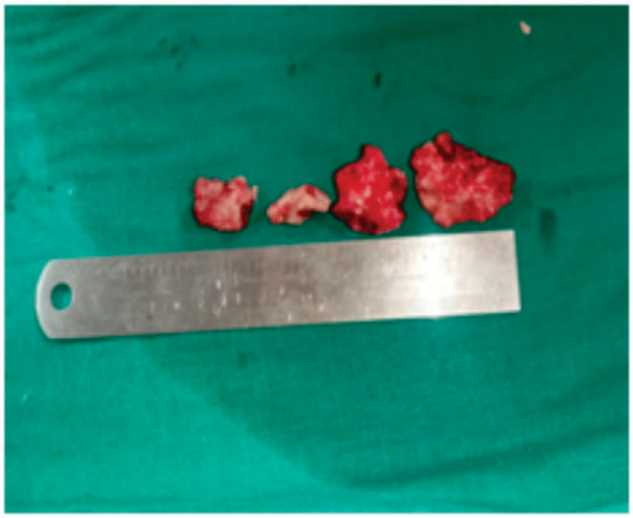

Figure 4: Extracted mandibular left second molar tooth with removal of calcified mass.

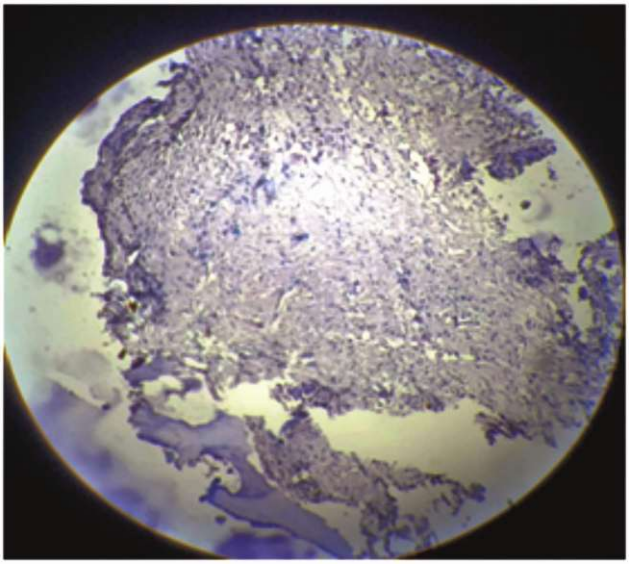

Figure 5: Histopathology of Ameloblastic fibro-odontome.

Histopathology showed strands, cords and islands of odontogenic epithelial cells with central stellate reticulum-like cells (Figure 5). Some of the follicles showed peripheral tall columnar cells with central stellate reticulum-like cells. The connective tissue was delicate and composed of thin collagen fibres and stellate shaped fibroblasts with areas resembling dental papilla-like tissue. The lesion revealed abundant eosinophilic material resembling mature dentine and dentinoid like areas along with enamel matrix, basophilic spherules resembling cementum. Peripherally parallel bundles of collagen was seen. Based upon the histopathological report, a final diagnosis of AFO was made.

The patient was reviewed after a week for suture removal with uneventful recovery and healing. There was no complaint of paresthesia and no sign of nerve injury. The patient was called for regular follow up till 6 months. No complications were noted.

DISCUSSION:

AFO is a rare mixed neoplasm of odontogenic epithelium with ectomesenchymal tissue with dental hard tissue formation.[1] The incidence of AFO varies from 0.3% to 1.7% among the odontogenic tumours, and 71 % only between 5 to 14 years with mean age of 9.4 years so it is also called as tumour of childhood.[1] AFO lesions have equal preponderance to mandibular and maxillary region with higher occurrence in posterior region. Males are affected more as compared to female.[5] Clinically, AFOs are asymptomatic and so the patient does not seek any consultation till the lesion becomes large in size causing facial disfigurement and bony expansion.[6] Delayed or unerupted tooth may also be one of the concern.[4] The unerupted or displaced tooth in apical direction obviates the origin of the lesion from tissue of dental origin primarily dental lamina.[5] In our case, the presenting feature was painless swelling in a teenage girl. As the swelling was painless, the consultation was done only when the swelling attained a size to be visualized externally. The delay in consultation may be because of the painless nature of the lesion, ignorance of patients belonging to uneducated farmer background, poor socioeconomic status and scarcity of experienced dental surgeons in rural areas.[7]

The exact histogenesis of AFO is controversial. Different studies have different opinions. Cahn and Blum[8] postulated the concept of continuum of differentiation i.e. least differentiated tumor gets transformed into well differentiated tumor. The origin of AFO is from Ameloblastic Fibroma (AF) which is a least differentiated tumour that gets transformed into a moderately differentiated form which is AFO and finally AFO into Complex Odontoma. But this concept was rejected by Slootweg et al[9] who found that AF and AFO are separate entity because:

a) The AFO which is a more differentiated form appears early in life than AF.
b) The site predilection of AFO is different from AF.
c) AF has neoplastic character but AFO has hamartomatous features.

Radiographically, AFO presents as well-demarcated circumscribed unilocular radiolucencies with variable amounts of calcifications.[6] In the present case we also observed the similar finding of a well - defined mixed lesion extending from distal root of the right 1st molar to the ramus of mandible and an unerupted 37 tooth was observed inside the mass.

AFO has been classified under developing odontoma in WHO classification (2017 and 2022) and are considered hamartomas rather than tumour but the presence of BRAF p.V600E mutation in AFO which is similar to that of AF and is absent in odontoma favours the argument that some lesions are neoplastic which manifest aggressive biological behavior (displacement and/or prevent eruption of teeth and continued rapid growth with cortical perforation) large size and reoccurrence.[4,10]

Histopathological section show islands and strands of odontogenic epithelium lined by tall columnar cells resembling ameloblasts and central stellate reticulum-like tissue scattered within a highly cellular connective tissue resembling primitive dental papilla. Decalcified H&E stained sections show

conglomerate mass of enamel and dentine arranged in a disorganized form .[4] In our case, the decalcified H&E stained section showed strands, cords and a few islands/ follicles of odontogenic epithelial cells. Some of the follicles show peripheral tall columnar cells with central stellate reticulum-like cells. The connective tissue was delicate and composed of thin collagen fibres and stellate shaped fibroblasts with areas resembling dental papilla-like tissue. The centre of the lesion showed abundant of eosionophilic material resembling mature dentine and dentinoid like areas along with enamel matrix, basophilic sperules resembling cementum. Abundant collagen fibres were seen in periphery.

The differential diagnosis include mixed odontogenic tumour like calcifying odontogenic cyst, calcifying odontogenic tumor, immature complex odontoma and odontoamelo-blastoma. AFO can be differentiated from calcifying epithelial odontogenic cyst by the presence of ghost cells within epithelial lining and calcifications.[4] In calcifying epithelial odontogenic tumor presence of liesegang ring is seen.[4] The term odontoamelo-blastoma exhibit histological features similar to ameloblastoma and complex odontoma.[4]

The recommended management for AFO is enucleation as the tumor is firmly encapsulated and has no tendency to invade the surrounding tissue. AFO is thought to be less aggressive and is effectively treated with enucleation with removal of the unerupted tooth. [1,2,5,8] Recurrence of 7.4% has been reported in literature which was attributed to failure to remove the lesion completely or unerupted or displaced tooth.[1] Malignant transformation of AFO is rare so long term follow up is essential.[11]

In the present case although the size of the lesion was more than 3 cm but lesion was well encapsulated without any local invasion curtailing the enucleation with removal of unerupted 37 and also extraction of 36 which had undergone external root resorption.

CONCLUSION:

AFO is a rare, benign mixed odontogenic tumor with nonspecific clinical and radiographic features. Histopathology can only confirm the diagnosis. Although the incidence of the lesion is less than 2 percent, it should always be considered in differential diagnosis of the mixed radiolucent radiopaque lesion in paediatric age groups. Owing to its well encapsulation, non-invasive nature, low aggressiveness and low recurrence, it is managed conservatively by enucleation with extraction of unerupted teeth. Long term follow up is mandated to know any malignant transformation.

DECLARATION OF PATIENT CONSENT:

The authors certify that they have obtained all appropriate patient consent forms. In the form, the patient(s)/guardian has/have given his/her/their consent for his/her/their images and other clinical information to be reported in the journal. The patients/guardian understand that their names and initials will not be published and due efforts will be made to conceal their identity, but anonymity cannot be guaranteed.

Financial Support and Sponsorship

Nil.

Conflicts of Interest

There are no conflicts of interest.

Acknowledgment- Dr Shubhangi Mhaske, Professor & Head, Dept of Oral Pathology, People's College of Dental Sciences and Research Centre, Bhopal.
Dr Abdul Rajjak Khandakar, Post Graduate Student. Department of Oral and Maxillofacial Surgery, People's Dental Academy, Bhopal.

REFERENCES:

1. Boxberger NR, Brannon RB, Fowler CB. Ameloblastic fibro-odontoma: a clinicopathologic study of 12 cases. J Clin Pediatr Dent. 2011 Summer;35(4):397-403. doi: 10.17796/jcpd.35.4.t3387t25865758w3. PMID: 22046699.
2. Hooker SP. Ameloblastic odontoma: an analysis of twenty-six cases. Journal of Oral Surgery. 1967;24:375–376. https://cir.nii.ac.jp/crid/ 1573950400144670080
3. Buchner A, Kaffe I, Vered M. Clinical and radiological profile of ameloblastic fibro-odontoma: an update on an uncommon odontogenic tumor based on a critical analysis of 114 cases. Head Neck Pathol. 2013 Mar;7(1):54-63. doi: 10.1007/s12105-012-0397-9. Epub 2012 Sep 22. PMID: 23001451; PMCID: PMC3597150.
4. Beena VT, Jose J, Paul S, Mathunny MS, Kottarathil SK, Shalu. Ameloblastic Fibro-odontoma. Oral Maxillofac Pathol J 2017;8(2):94-97.DOI: 10.5005/jp-journals-10037-1108.
5. A Goel, M., Qamar, A., Daftary, M., Chhabile, S.R., Pundkar, S., & Sharma, M. (2023). Ameloblastic fibro-odontoma in the posterior mandible: A case report. Medicine International, 3, 63. https://doi.org/10.3892/

mi.2023.123.
6. Reddy YI, Prakash AR. Ameloblastic Fibro-odontome (AFO) of the Mandible: A Case Report. J Clin Diagn Res. 2014 Jan;8(1):260-2. doi: 10.7860/JCDR/2014/5402.3942. Epub 2014 Jan 12. PMID: 24596790; PMCID: PMC3939569.
7. Tine SD, Tamba B, Niang PA, Dial CM, Gassama BC, Diatta M, et al. Report of a rare case of ameloblastic fibro-odontoma of the mandible with >400 odontomas and a related literature review. Médecine Buccale Chirurgie Buccale,2017;23(2):99–102. https:// doi.org/10.1051/mbcb/2016055
8. Cahn LR, Blum T. Ameloblastic odontoma: Case report critically analyzed. J Oral Surg 1952;10:169-70.https://doi.org/10.1016/0030-4220(81)90056-6
9. Slootweg PJ. An analysis of the interrelationship of the mixed odontogenic tumors--ameloblastic fibroma, ameloblastic fibro-odontoma, and the odontomas. Oral Surg Oral Med Oral Pathol. 1981 Mar;51(3):266-76. doi: 10.1016/0030-4220(81)90056-6. PMID: 6938886.
10. Soluk-Tekkesin M, Wright JM. The World Health Organization Classification of Odontogenic Lesions: A Summary of the Changes of the 2022 (5th) Edition. Turk Patoloji Derg. 2022;38(2):168-184. doi: 10.5146/tjpath.2022.01573. PMID: 35578902; PMCID: PMC9999-699.
11. Howell RM, Burkes EJ Jr. Malignant transformation of ameloblastic fibro-odontoma to ameloblastic fibrosarcoma. Oral Surg Oral Med Oral Pathol. 1977 Mar;43(3):391-401. doi: 10.1016/0030-4220(77)90326-7. PMID: 265043.

Case Report

Down Syndrome: A Case Report with Concise Review

Christopher Vinay Shinde[1], Sahil Kohli[2], Vini Shinde[3]

[1]Department of Oral Medicine and Radiology, People's Dental Academy, People's University, Bhopal (Madhya Pradesh), [2]RKDF Dental College and Research Centre, Bhopal, [3]Department of Oral Pathology and Microbiology, People's Dental Academy, People's University, Bhopal (Madhya Pradesh)

ABSTRACT:

Down Syndrome is a common disorder with phenotypes including leukemia, congenital heart defects and Alzheimers disease. It is a chromosomal abnormality which leads to mild to moderate intellectual ailment and this impairment causes dysfunctioning of multiple organs including the orofacial region. The extra genetic material can result in disturbed mental and physical growth of the child. Mental retardation, delayed language and motor development, delay in fetal brain growth, prenatal and postnatal growth deficiency, gastrointestinal malformations, congenital hematologic disorders, and cardiac abnormalities are observed in this disorder. Dental and craniofacial features include brachycephaly, flat occiput, mandibular prognathism and reduction in parotid salivary flow rate. Necrotizing ulcerative gingivitis, periodontal disease and delay in eruption of both deciduous and permanent teeth is observed in this disorder. This article aims to discuss the clinical features and management of a six year old male child showing classical signs of this disorder.

KEY WORDS: Down's syndrome, disorder, growth, deficiency

Address for correspondence : Dr. Sahil Kohli, Reader, Department of Oral Medicine and Radiology, RKDF Dental College and Research Centre, Bhopal (Madhya Pradesh) , India, E-mail: sahilkohlisk11@gmail.com

Submitted: 06.09.2025, **Accepted:** 12.12.2025, **Published:** 26.12.2025

INTRODUCTION:

Down syndrome is a common chromosomal anomaly in which distinctive phenotypic features and psychomotor developmental delays are observed. There is presence of all or portion of third copy of chromosome 21, and that is why it is also known as trisomy 21 or trisomy G. A Britisher named John Langdon Down first observed and identified this disease in the year 1886, and hence it is known as Down Syndrome.[1] The incidence of Down Syndrome is calculated to be 1 per 800 to 1000 births. In India, the frequency is 2.2 per 1000 live births. It is an abnormality of chromosome 21,which is the smallest human chromosome. It ranges over 48 million base pairs which are the building blocks of DNA and it represents 1.5 to 2 percent of total DNA in cells.[2] Various medical complications like neurological, cardiac, cognitive and orthopaedic disorders can be observed in this disorder. There is increased risk of Alzheimers disease, congenital heart disease, leukemia, dementia, seizure disorders, vision and hearing difficulty, gastrointestinal complications, sleep apnea, disturbance in endocrine system, musculoskeletal deformity and excess mobility of atlas and axis are observed in this disorder.[3] Severe degree of intellectual disability, physical growth disturbance, neotenization of brain and mental retardation are common in this syndrome. The orofacial features include high arched or oval palate, maxillary canine impaction and underdeveloped maxilla.[4] Development of this syndrome is associated with decrease in the neuronal number and abnormal neuronal differentiation. In a patient suffering from this syndrome,neurons deteriorate and undergo apoptosis. Busciglio J et al observed that deterioration of neurons can be prevented by treating with free radical scavengers.[5]

Access this article online

Quick Response Code:	Website: www.pjsr.org
	DOI: https://doi.org/10.5281/zenodo.18065975

This is an open access journal, and articles are distributed under the terms of the Creative Commons Attribution-Non Commercial ShareALike 4.0 License, which allows others to remix, tweak, and build upon the work non-commercially, as long as appropriate credit is given and the new creations are licensed under the identical terms.
For reprints contact: editor.pjsr@peoplesuniversity.edu.in

How to cite this article: Shinde CV, Kohli S, Shinde V. Down Syndrome: A Case Report with Concise Review. PJSR. 2025;18(2):74e.

Figure 1: Frontal & side view showing features of Down's syndrome.

Figure 2: Intraoral examination of maxillary &mandibular arches showed malocclusion with delayed tooth eruption, retained central incisors, lingually placed 61,71 & 81 and peg shaped maxillary lateral incisors.

CASE REPORT:

A six year old male patient reported to the Department of Oral Medicine and Radiology for routine dental check-up. Despite having poor speech ability, the patient was able to understand the given instructions. Frankl behaviour rating scale indicated the child's behaviour as definitely positive. Medical history revealed that the patient was diagnosed with Down syndrome by his physician 5 years ago and surgical management of the patient has been done. On general examination, patient was found to be conscious and cooperative but he was short statured and mentally challenged. Extraoral examination showed hypertelorism, squint in the eyes, and upward inclination to the eyes, depressed nasal bridge, slanting of palpebral fissures, medial epicanthal folds and brachydactyly (Figure 1). On intraoral examination, malocclusion was observed with delayed tooth eruption. There was retained deciduous teeth that is retained central incisors in maxilla and mandible. The maxillary central incisors on the left side of the patient were palatally placed (61) and the mandibular central incisors were also found to be lingually placed (81 and 71).Maxillary lateral incisors were found to be peg shaped. High arched and constricted palate was observed in the patient. Tongue appeared to be fissured which protrudes on mastication (Figure 2). Anterior open bite was observed. Dryness of mouth due to mouth breathing was present. Due to severe malocclusion, erythematous gingival with bleeding on probing, stains and calculus was present. This showed poor oral hygiene with halitosis. However, no hearing loss was observed in the patient. A provisional diagnosis of Down Syndrome was given and radiograph was advised.

RADIOGRAPHIC FEATURE:

Orthopantomograph showed short mandibular ramus with a steep mandibular angle and mild prominence of the antegonial notch. Crowding of teeth, underdeveloped condylar and coronoid process were observed. Inverted cone shape was seen with respect to 51 and ill-defined periapical radiolucency was seen with respect to 81 and 71. Coronal radiolucency was seen involving enamel, dentin and pulp. There was generalized decrease in the height of the alveolar bone extending below roots of most teeth which indicated vertical bone loss. (Figure 3)

Figure 3: OPG showed crowding of teeth, underdeveloped condylar and coronoid process.

Correlating the clinical and radiological features, a diagnosis of Down syndrome was made. Oral prophylaxis was done and orthognathic surgery was advised. Psychological counselling was given to the patient and parents.

DISCUSSION:

Down Syndrome is a chromosomal disorder and can cause intellectual deformity, congenital heart disease, Alzheimer's disease, leukemia and Hirschsprung disease. Low muscle tone, folding of skin on the inner corner of the eyes, upward-slanted eyes,

abnormal shaped ears, deeply felt wrinkle over the focal point of the palm, and enlarged tongue with a little nose are some of the features.[6] There are 3 genotypes of Down Syndrome and they are trisomy 21,translocation and mosaicism, out of which trisomy 21 is most common.[1] Premature birth,prenatal and postnatal deficiency of growth, delayed osseous maturation, flaring of iliac wings, brachymesophalangy of the fifth finger, poor verbal short term memory, disturbed auditory sequencing, disturbed color retention, disturbed visual-motor task, atrial septal defect, gastrointestinal disturbances such as tracheo-esophageal fistula, pyloric stenosis and annular pancreas are commonly observed in this disorder. Hyperkeratosis, seborrheic dermatitis, leukemia and lymphoma can occur. Retinoblastomas, pancreatic and bone tumors are also observed in this disorder.[2] In this syndrome, age of mother conceiving pregnancy is an important risk factor because as age increases risk of chromosomal abnormality increases.[7] Dental and craniofacial features include deep and high palate, bifid uvula, underdeveloped nose, low nasal bridge, cleft lip, cleft palate, underdeveloped jaw, abnormal lip closure, hypotonic lips, abnormal movement of tongue, fissured tongue, anterior open bite and muscle hypotonia.[6] There is reduction in flow rate of saliva. There is absence of frontal and sphenoidal sinus but fontanelles are large. Bony midface hypoplasia, mandibular prognathism and ocular hypotelorism is common. In most cases, maxillary sinuses are hypoplastic. Brachycephaly is common in such patients. Periodontal disease and necrotizing ulcerative gingivitis are common in such patients. There is delay in eruption of both deciduous and permanent teeth. The eruption process is disturbed because in some cases, deciduous first molars exist before incisors. Third molars, second premolars and lateral incisors are mostly absent in permanent dentition. Deciduous lateral incisors can also be absent. Sometimes, the maxillary lateral incisors are peg shaped. Enamel hypoplasia, enamel hypocalcification, widely spaced teeth and posterior crossbite can occur in such patients.[2]Dental caries can be observed in such patients due to immunosuppression where pathogens colonize and demineralise the tooth surface causing cavitation. Macroglossia, malocclusion and bruxism can also be present.[1]In such patients, there can be difficulty in providing strong anesthetic effect to patient because these patients are comparatively more sensitive to pain than other individuals, so there can be delayed but magnified pain response. Microdontia, taurodontism, reduced occlusal vertical dimension and atypical shape of dental crowns can be observed.[8] Ultrasound and maternal blood screening are some of the noninvasive diagnostic methods which can indicate this syndrome. Amniocentesis and chorionic villus sampling are diagnostic methods which can confirm the presence of an extra chromosome 21. Karyotyping, which is a blood test, can also be helpful diagnostic tool in identifying this syndrome.[9] Regular medical check ups and monitoring should be done in such patients. Early intervention services are useful in such patients because they help in identifying delay in normal physical and mental growth of the patient. Speech therapy, occupational therapy, behaviour therapy and social skills training can be helpful in such patients. A psychologist can monitor such patients so that they can deal with day to day challenges. A balanced and nutritious diet is important for such patients.[10]

Ventricular septal defect(VSD) is common in such patients.It is a cardiac disorder in which a hole is present in the septum which seperates the two ventricles of the heart. In such patients, the oxygen rich blood travels from left ventricle, through the opening in the interventricular septum and then mix with blood having less oxygen in the right ventricle. Reduced oxygenated blood provides less oxygen to body tissues resulting in hypoxia, disturbed cellular metabolism and decreased rate of respiration. Treatment of such patients using general anesthesia should be avoided as it can cause serious side effects such as sudden increase in pulmonary vascular resistance, hypoxia, hypercapnia, hypothermia, acidosis and hyperinflation of lungs. Non pharmacological behaviour management methods such as voice control and tell-show-do (TSD) are useful.[11] The orofacial features caused by genetic disorder and those acquired in later life must be identified. For specific treatment of patients suffering from Down Syndrome, it is important to identify features which are epigenetic. Large cranial base angle, reduced size of cranial base, decrease in length of maxilla and increase in length of mandible leads to skeletal class III malocclusion. According to Moss's functional matrix theory, development of the alveolar process occurs because of inductive growth potential of the teeth.[12] Chavan et al conducted a study to assess and observe the effect of Pilates training on children suffering from Down Syndrome. In this study, children suffering from this disorder, from 8 to 18 years of age, were randomly divided into two groups. Pilates training was provided to group A and group B was control group. The exercises were conducted for 12 sessions, five days in a week. The session duration was 30 minutes including warm up and cool down period. It was found that Pilates is a successful training program to increase the cardiopulmonary functions in children suffering from this syndrome.[13] Nuchal translucency (NT) is helpful

in identifying about 83% of trisomy 21 pregnancies in the first trimester. NT is a psysiological process marker in the fetus that reflects the fetal lymphatic and vascular growth in head and neck region.[14] Our case report further emphasizes the importance of dental consultation and further requirement of invasive surgical procedures to be important in the management of the cases of Down Syndrome.

CONCLUSION:

Early diagnosis of Down Syndrome and identification of its orofacial features is important for improving physiological, psychological, medical and dental quality of life. In such patients, it is important to execute preventive methods to avoid oral health issues and address long term consequences. A tailored prevention strategy is required for such patients. This includes parental education and participation, regular orofacial assessment starting at 12-18 months, providing balanced diet, oral prophylaxis and hygiene motivation. For oral hygiene, there can be modification of toothbrushes to help such patients. Electric toothbrushes can be helpful in such cases. Interim therapeutic restoration, using materials such as glass ionomers that release fluoride, play an important role in both preventive and therapeutic techniques. Some patients may show anxiety with uncooperative behaviour. Behavioural reinforcement techniques such as tell-show-do, desensitization, sedation, verbal and non verbal communication, distractions and euphemisms may be helpful. During first six months, surgical management of cardiac defects is advised. Antibiotics, leukemia therapies and anticonvulsive drugs also play an important role in the management of patients suffering from this disorder. Careful monitoring of such patients by specialists such as cardiologist, pediatrician, neurosurgeon, orthopaedic surgeon and psychiatrist should be done.

DECLARATION OF PATIENT CONSENT:

The authors certify that they have obtained all appropriate patient consent forms. In the form, the patient(s)/guardian has/have given his/her/their consent for his/her/their images and other clinical information to be reported in the journal. The patients/guardian understand that their names and initials will not be published and due efforts will be made to conceal their identity, but anonymity cannot be guaranteed.

Financial Support and Sponsorship

Nil.

Conflicts of Interest

There are no conflicts of interest.

REFERENCES:

1. Madhusudhan KS, Subramaniam P, Rathnashree MV, Oral Rehabilitation in a Down Syndrome patient -a case report. Inter. J. Res. Dental Sci. 2023;5(3):11-18.
2. Gopal KS, Hemanthakumar S. Down Syndrome : Report of a case and review of literature. IJACR. 2017;4(7):238-244.
3. Karkera S. A current knowledge of 'Down Syndrome:A Review'. IJDMSR 2021;3(1):805-810. DOI:10.35629/5252-0301805810
4. HarshithaaN,Maragathavalli G. Case report Down's Syndrome (Trisomy 21) IOSR-JDMS 2014;13(1):03-04. DOI:10.9790/0853-13170304
5. Mathew AK,Amaladas AS,Ahmed A,Hameed S.Clinical presentation of Down's Syndrome:a case report JMR 2017;3(3):107-109. DOI:10.31254/jmr.2017.3304
6. Khandelwal D, KalraN,TyagiR,KhatriA,KumarS,Afsal MM. Dental management of a patient with Down Syndrome: a case report and review of literature.Indian J Case Reports 2019;5(1):33-35. DOI: https://doi.org/10.32677/IJCR.2019.v05.i01.011
7. Nadeem MT,Afreen S,Tabassum K,Jalal M. Down's Syndrome: A Case Report IJSR 2018;7(5):42-43.https://www.researchgate.net/publication/325544475_DOWN'S_SYNDROME_A_CASE_REPORT
8. Thanvi C, Prasad AB, Raisingani D, et al. Dental Aspect of Down Syndrome: A Case Report. J Mahatma Gandhi Univ Med Sci Tech 2018;3(3):108–112. https://doi.org/10.5005/jp-journals-10057-0093
9. Tiwari S,Singh K,Patel P,Prakash K,Verma S. Advancements and interventions in Down Syndrome: A comprehensive review of current research and clinical endeavors. Glob J PharmaceuSci 2024;11(3):001-0010. DOI: 10.19080/GJPPS.2024.11.555812
10. Grewal T,Kumar M. Down Syndrome:An Overview IJCRT 2024;12(3):686-704. https://ijcrt.org/papers/IJCRT2403335.pdf
11. Dev S. Down syndrome with ventricular septal defect- a case report of surgical extraction.Int J PedodRehabil 2021;6:60-2. 10.4103/ijpr.ijpr_46_20
12. Klingel D, Hohoff A, Kwiecien R, Wiechmann D, Stamm T. Growth of the hard palate in infants with Down syndrome compared with healthy infants-A retrospective

case control study. PLoS One. 2017 Aug 10;12(8):e0182728. doi: 10.1371/journal.pone. 0182728. Erratum in: PLoS One. 2018 Sep 7;13(9):e0203899. doi: 10.1371/journal. pone.0203899. PMID: 28796822; PMCID: PMC5552113.

13. Chavan P,Shah V,Chavan S. Effect of pilates on cardio-respiratory functions in children with Downs Syndrome IJSR 2022;11(1):1-3. DOI : 10.36106/ijsr
14. Kazemi M, Salehi M, Kheirollahi M. Down Syndrome: Current Status, Challenges and Future Perspectives. Int J Mol Cell Med. 2016 Summer;5(3):125-133. Epub 2016 Aug 10. PMID: 27942498; PMCID: PMC5125364.

INDEXED JOURNAL

Index Copernicus
Google Scholar
EBSCO host
Indian Citation Index
IP Indexing
National Science Library (NISCAIR)

Index Copernicus value (ICV 2024) : 99.97

INSTRUCTIONS TO AUTHOR

'People's Journal of Scientific Research' is a peer reviewed official journal of People's University, whose purpose is to publish research papers, short communications, review articles including book reviews and informative articles on all scientific subjects of Health Sciences (Medical, Dental, Nursing, Paramedical including Behavioral and Social Sciences), Pharmaceutical Sciences, Life Sciences (Biotechnology, Microbiology, Biochemistry, Immunology, Molecular Biology, Bioinformatics etc).

- The Editor, reserves the right to improve on style, grammar & make corrections in the manuscript accordingly.
- Manuscript should be submitted online with photographs/illustrations in JPEG / TIFT format only.
- Manuscript should be accompanied with author's declaration form.
- Minimum size of photograph / illustration should be 8x10 cm.
- **The size of manuscript (excluding abstracts, tables, references & figures/photographs) will be limited to 2500 words for full articles and 1200 words for case reports or as deemed necessary.**

All manuscripts must be accompanied by the following Declaration:

In consideration of PJSR accepting the manuscript in review, undersigned author (s) hereby grant the Publisher an exclusive licence to publish their original research paper and to reproduce, recreate, extract and distribute worldwide in various languages, forms, formats, and media. Authors retain the copyright of the articles. The author (s) warrants that the article is original, is not under consideration by any other journal, has not been previously published and takes responsibility for the contents. Furthermore, I/we warrant that all investigations reported in the publication were conducted in conformity with the recommendations from the Declaration of Helsinki and the International Guiding Principles for Biomedical Research involving animals. **That the Ethical Committee clearance has been obtained for experiment on animals or trial involving human beings. Financial interests, sources of outside support and conflict of interest that exist for individual contributors in connection with the content of this paper have been disclosed.** We give the rights to the corresponding author to make necessary changes as per the request of the journal, do the rest of the correspondence on our behalf and he/she will act as the guarantor for the manuscript on our behalf. My work is a part / not a part of dissertation.

Title of the paper:.....

Author's name (s) In order of appearance in manuscript	**Signature**	**Date**
(1) ……	……	.....…
(2) ……	……	.....…

The manuscript will be considered for publication based on their scientific merit, originality, clinical significance, validity of the material presented and readability. The submitted manuscript will be reviewed by two or more referees who will determine, the publishing prospects of the article, on the basis of the MRS (Manuscript Rating Score).

Article (s) should be sent to Dr. Anish Gupta, Editor -In- Chief, People's Journal of Scientific Research, Room No. 33, People's University Building, Bhanpur, Bhopal – 462037, Ph. No.: 0755 4005435 (Office), E-mail : editor.pjsr@peoplesuniversity.edu.in, editor.pjsr@gmail.com , Website: www.pjsr.org

Issue Information - **Dr Anish Gupta**

ORIGINAL RESEARCH ARTICLES

Undergraduate Dental Students' Perceptions of Periodontics Training: A Cross-Sectional Questionnaire Survey
Madhumitha C, Rajesh Gaikwad, Akshaya Banodkar, Nilofar Attar, Nandini Metaliya, Akhrienuo Kiso......01
https://doi.org/10.5281/zenodo.17974550

Awareness and Knowledge of the Role of Probiotics and Prebiotics in Periodontal Health Among Undergraduate Dental Students: A Cross-Sectional Survey
Nandini Metaliya, Akshaya Banodkar, Rajesh Gaikwad, Gulnar Sethna, Madhumitha C, Akhrienuo Kiso 11
https://doi.org/10.5281/zenodo.17975212

Assessment of Modifiable Risk Factors Among Type 2 Diabetes Mellitus Patients
Manu Gupta, Afreen Ali, Rajkumar Upadhyay, OP Nayak......21
https://doi.org/10.5281/zenodo.17984045

REVIEW ARTICLES

Provisionalization in Prosthodontics: A Literature Review
Supriya Singh, Shitij Srivastava, Abhinav Shekhar, Abhishek Singh......26
https://doi.org/10.5281/zenodo.17998395

Nutritional Deficiencies and their Impact on Oral Health
Uditi Bhadra, Sakshi Deshmukh, Swati Shrikant Gotmare......35
https://doi.org/10.5281/zenodo.18058731

CASE REPORTS

ODONTOGENIC KERATOCYST A Relapse that Refuses to Rest - A Case Report
Avni Shrivastava, Namrata Jain, Priyanshi Wasalya, Delphina Michael Kapoor 42
https://doi.org/10.5281/zenodo.18045654

Pseudocyesis or Delusion of Pregnancy- A Case Report
Garima Tomar, Akshay Upadhyay, Anshul Shakya, Vaibhav Dubey..... 46
https://doi.org/10.5281/zenodo.18046085

Escitalopram-induced Bullous Pemphigoid: A Case Report
Akshay Upadhyay, Anshul Shakya, Garima Tomar, Vaibhav Dubey.....49
https://doi.org/10.5281/zenodo.18058250

Diagnostic & Management Dilemma in Atropine induced Psychosis with Restless Leg Syndrome – A Case Report
Anshul Shakya, Garima Tomar, Akshay Upadhyay, Vaibhav Dubey.....53
https://doi.org/10.5281/zenodo.18058286

ONLINE ONLY - REVIEW ARTICLES

Prosthodontic Management of Fractured Implant and Components: A Literature Review
Akshat Srivastava, Shitij Srivastava, Abhinav Shekhar, Love Kumar Bhatia.....56e
https://doi.org/10.5281/zenodo.18060127

Significance of Orofacial Manifestations Associated with Anemia: A Review
Sahil Kohli, Christopher Vinay Shinde, Vini Shinde.....63e
https://doi.org/10.5281/zenodo.18060463

CASE REPORTS

Ameloblastic Fibro-Odontoma - An Insight into its Clinico-Histopathological, Radiographic Features and its Surgical Management
Neha Jain, Ajay K Pillai, Annant Choubey, Amit Kumar Giri.....69e
https://doi.org/10.5281/zenodo.18065864

Down Syndrome: A Case Report with Concise Review
Christopher Vinay Shinde, Sahil Kohli, Vini Shinde.....74e
https://doi.org/10.5281/zenodo.18065975